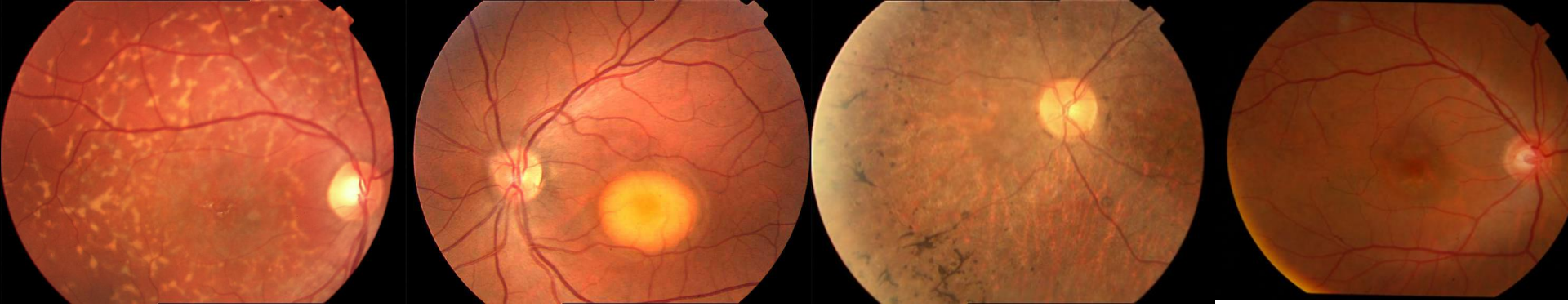

RETİNA DİSTROFİLERİ

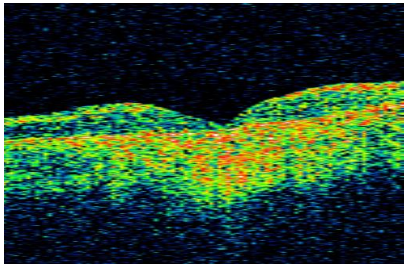

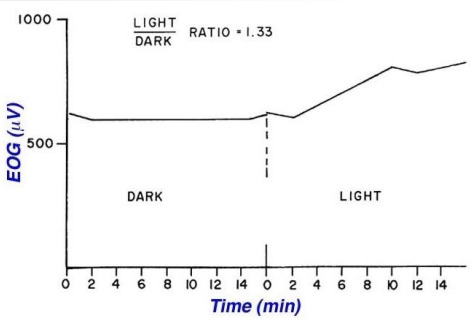

Dr. Şengül Özdek

GAZİ ÜNİVERSİTESİ GÖZ HASTALIKLARI

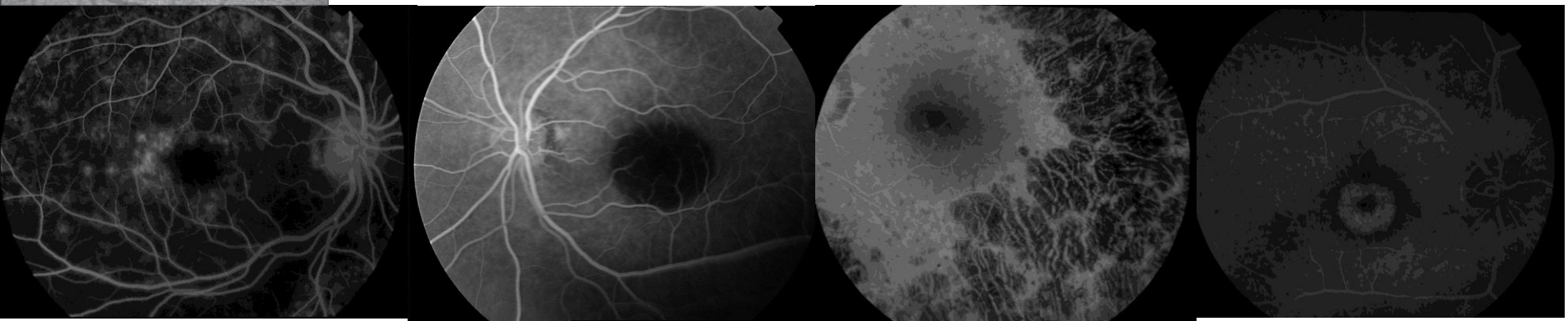

RETİNA DİSTROFİLERİ

- Genetiği karmaşık
- Geri dönüşümü (-)
- Fotoreseptör hasarı
- Etkin tedavi (-)
- Birbiri ile örtüşebilen
- Kalıtsal

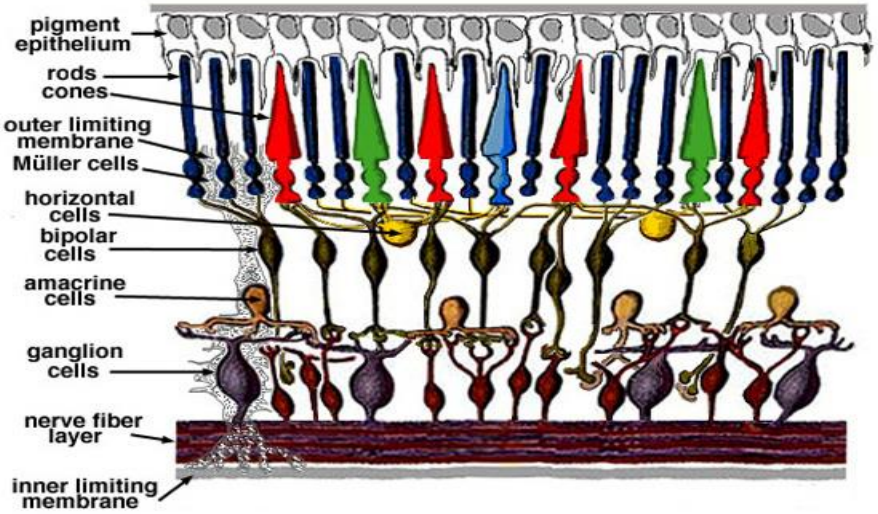

RETİNA DİSTROFİLERİ

- **I. YAYGIN FOTORESEPTÖR DİSTROFİLERİ**
  - ROD-KONİ DİSTROFİLERİ (RETİNİTİS PİGMENTOZA)
  - KONİ VE KONİ ROD DİSTROFİLERİ:
- **II. MAKÜLA VE RPE DİSTROFİLERİ**
  - STARGARD HASTALIĞI (F. FLAVİMAKÜLATUS)
  - BEST HASTALIĞI
  - PATERN DİSTROFİLER, DOM. DRUSEN
  - NORTH CAROLINA M.DİSTROFİ
  - SORSBY MAKÜLER DİSTROFİ
- **III. KOROİDAL DİSTROFİLER**
  - YAYGIN DEJENERASYONLAR: KOROİDEREMİ, GYRATE ATROFİ
  - BÖLGESEL VE SANTRAL KOROİDAL DİSTROFİLER:
    - SANTRAL AREOLAR KOROİDAL DİSTROFİ,

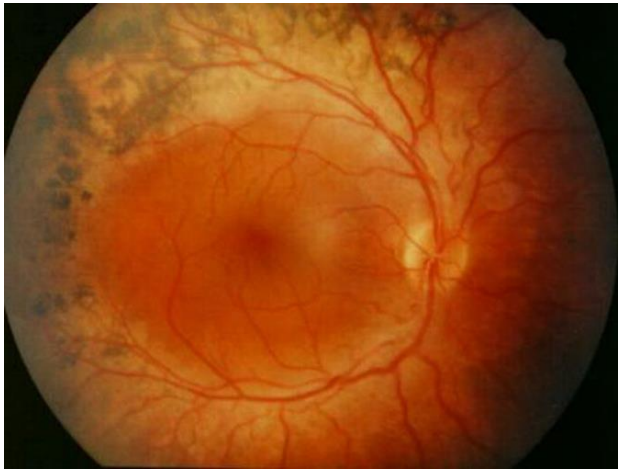

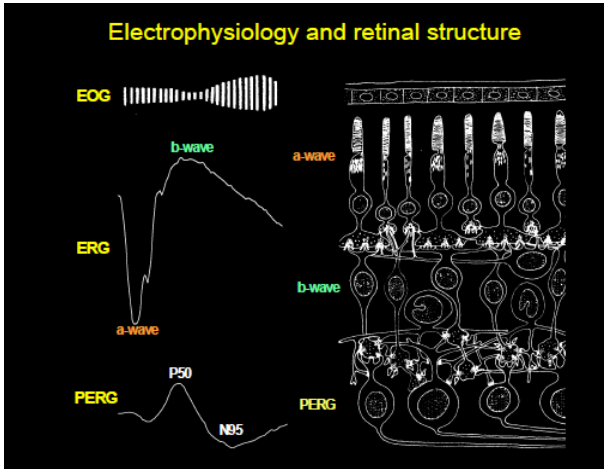

Tanımlanmış Gen mutasyonları

- **RETİNİTİS PİGMENTOSA**
  - Autosomal Recessive Retinitis Pigmentosa (arRP) / Sporadic Retinitis Pigmentosa Panel (7 genes) - USH2A, EYS, ABCA4, RPE65, PDE6A, PDE6B, and CRB1
  - Autosomal Dominant Retinitis Pigmentosa (adRP) - RHO, PRPH2, IMPDH1, RP1, PRPF8, PRPF31 and PRPF3 and CRX
  - X-linked Retinitis Pigmentosa (XLRP) - RP2
- **Choroideremia** - CHM
- **X-linked Juvenile Retinoschisis -** XLRS1
- **Stargardt Disease / Fundus Flavimaculatus** - ABCA4
- **CONE-ROD DYSTROPHY**
  - Autosomal Recessive Cone-rod dystrophy - ABCA4
  - Autosomal Dominant Cone-rod dystrophy - PRPH2, CRX
- **Leber congenital amaurosis**
  - Autosomal Recessive Leber Congenital Amaurosis **-** RPE65**,** CRB1, GUCY2D, AIPL1, CEP290
  - Autosomal Dominant Leber Congenital Amaurosis - CRX, IMPDH1

YAYGIN FOTORESEPTÖR DİSTROFİLERİ

ROD-KONİ DİSTROFİLERİ (RETİNİTİS PİGMENTOZA)

- Gece görme azlığı,
- Görme alanında daralma
- Kemik spikül benzeri pigmentasyon
- ERG'de fotoreseptör hasarı

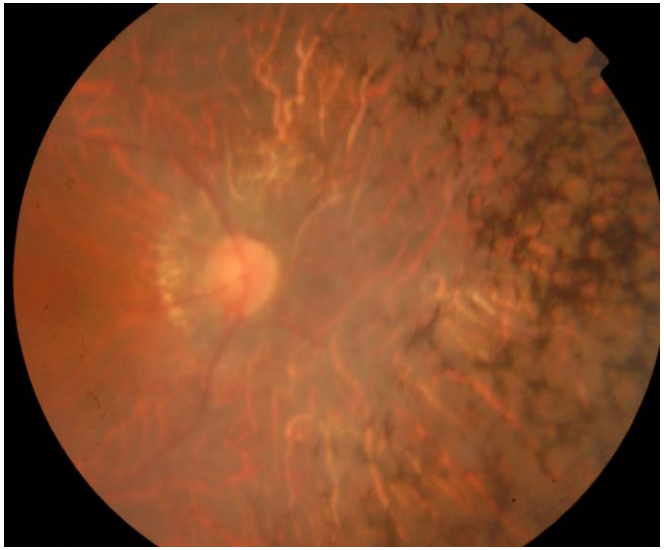

Klasik fundus bulguları

- Retina damarlarında incelme
- RPE atrofisine bağlı granüler görünüm
- İntraretinal kemik spikülü pigmentasyon
- Optik sinir başında solukluk
- Simetrik tutulum

- Retina damarlarında incelme
- RPE atrofisine bağlı granüler görünüm
- İntraretinal kemik spikülü pigmentasyon
- Optik sinir başında solukluk
- Simetrik tutulum

- Retina damarlarında incelme
- RPE atrofisine bağlı granüler görünüm
- İntraretinal kemik spikülü pigmentasyon
- Optik sinir başında solukluk
- Simetrik tutulum

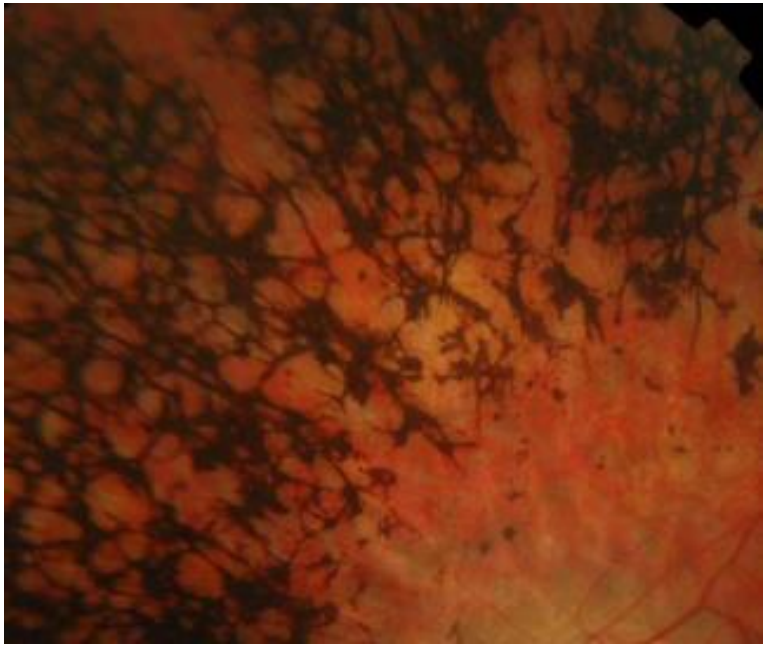

- Retina damarlarında incelme
- RPE atrofisine bağlı granüler görünüm
- İntraretinal kemik spikülü pigmentasyon
- Optik sinir başında solukluk
- Simetrik tutulum

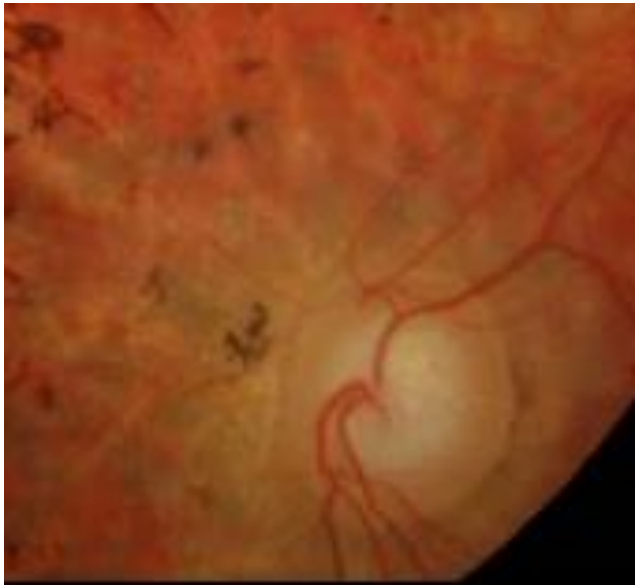

- Retina damarlarında incelme
- RPE atrofisine bağlı granüler görünüm
- İntraretinal kemik spikülü pigmentasyon
- Optik sinir başında solukluk
- Simetrik tutulum

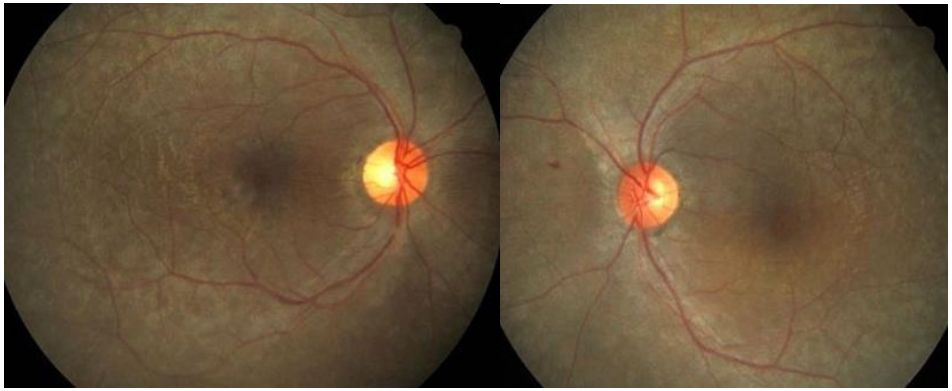

RP – Santral görme kaybı

- Maküla ödemi (KMÖ-diffüz sızıntı)
- Selofan makülopati
- Atrofik makülopati

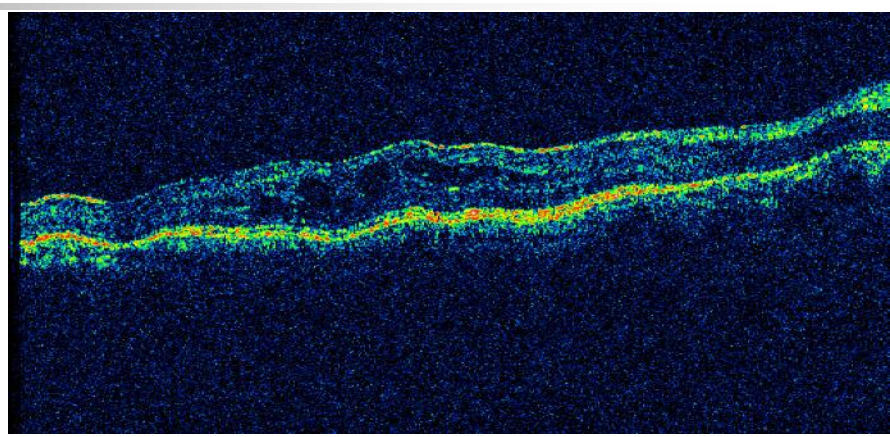

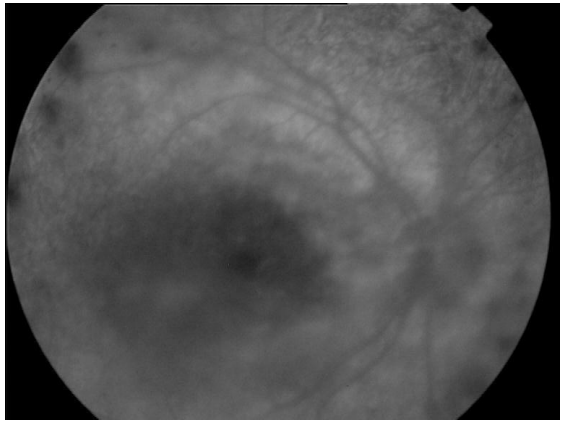

RP – Santral görme kaybı

- Maküla ödemi (KMÖ-diffüz vask sızıntı)
- Selofan makülopati
- Atrofik makülopati

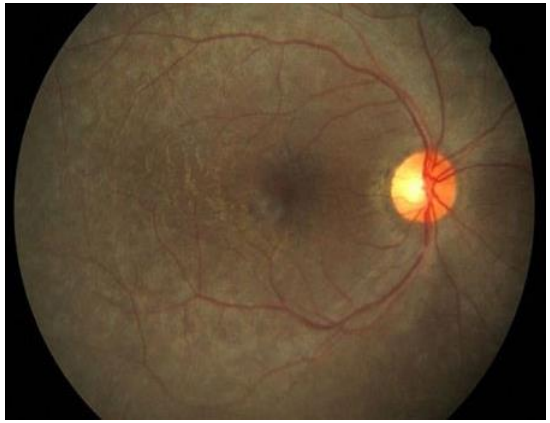

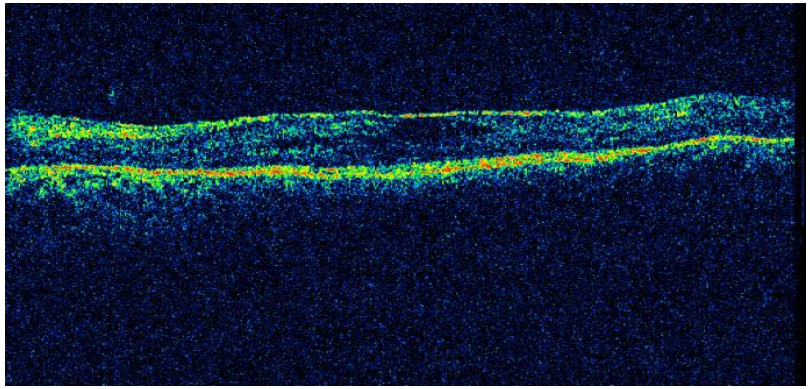

RP – Santral görme kaybı

- Maküla ödemi (KMÖ-diffüz vask sızıntı)
- Selofan makülopati
- Atrofik makülopati

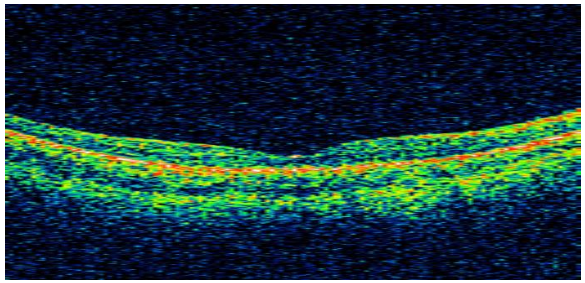

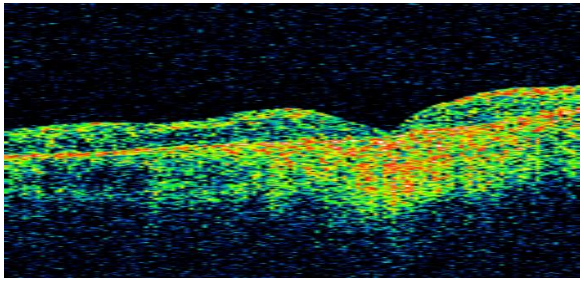

ERG

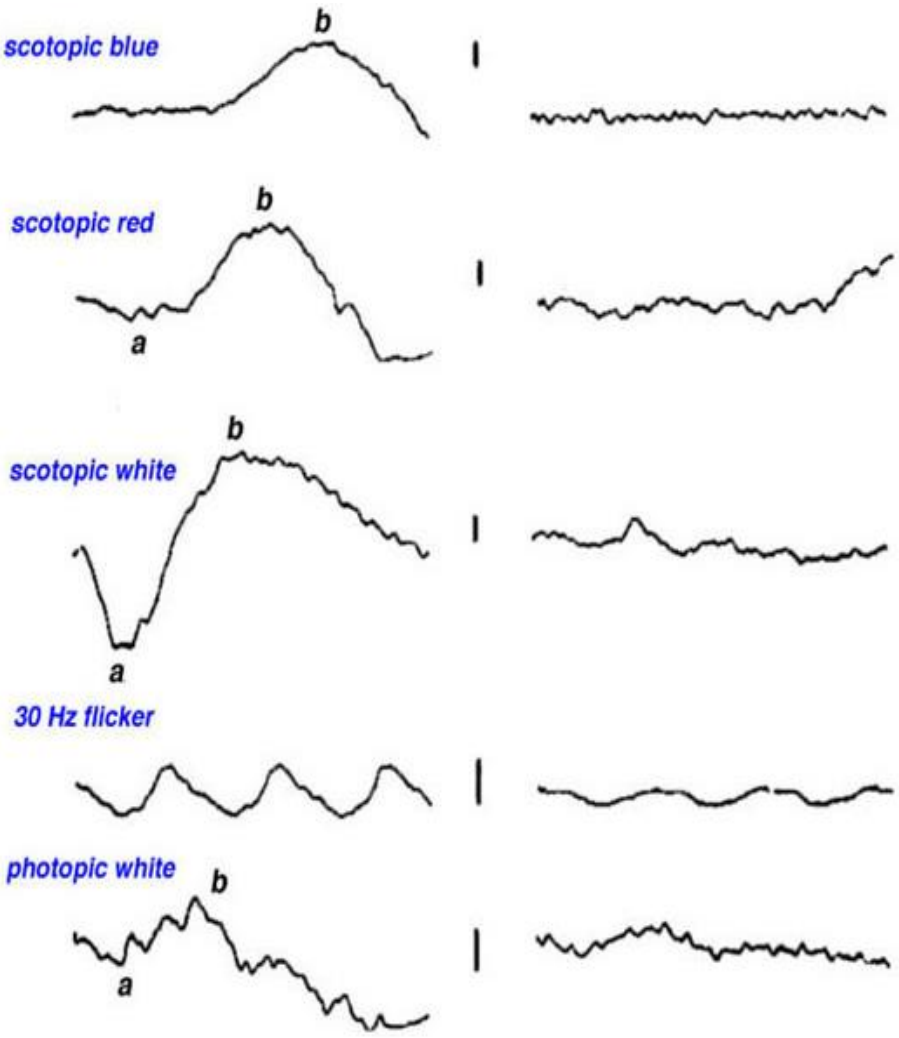
scotopic blue
b
scotopic red
b
a
scotopic white
b
a
30 Hz flicker
photopic white
b
a

RETİNİTİS PİGMENTOZA-Kalıtım

- Otozomal Dominant: %20-40 (En iyi)
- Otozomal Resesif…%30
- X'e bağlı resesif: %10
  - En erken yaşta başlar: 30y legal körlük!
- Sporadik: aile hikayesi (-) %20

Olgu: 46y, E, görme azlığı

- 10-20 yaş arası dönemden beri gece körlüğü
- Normal okul eğitimi
- 30 yaşına kadar araba kullanabiliyor
- Görme alanında giderek artan daralma, görmede azalma
- Aile hik: Anne, kız kardeş, dayı, dede de görme azlığı

GK: 0.2 / 0.3

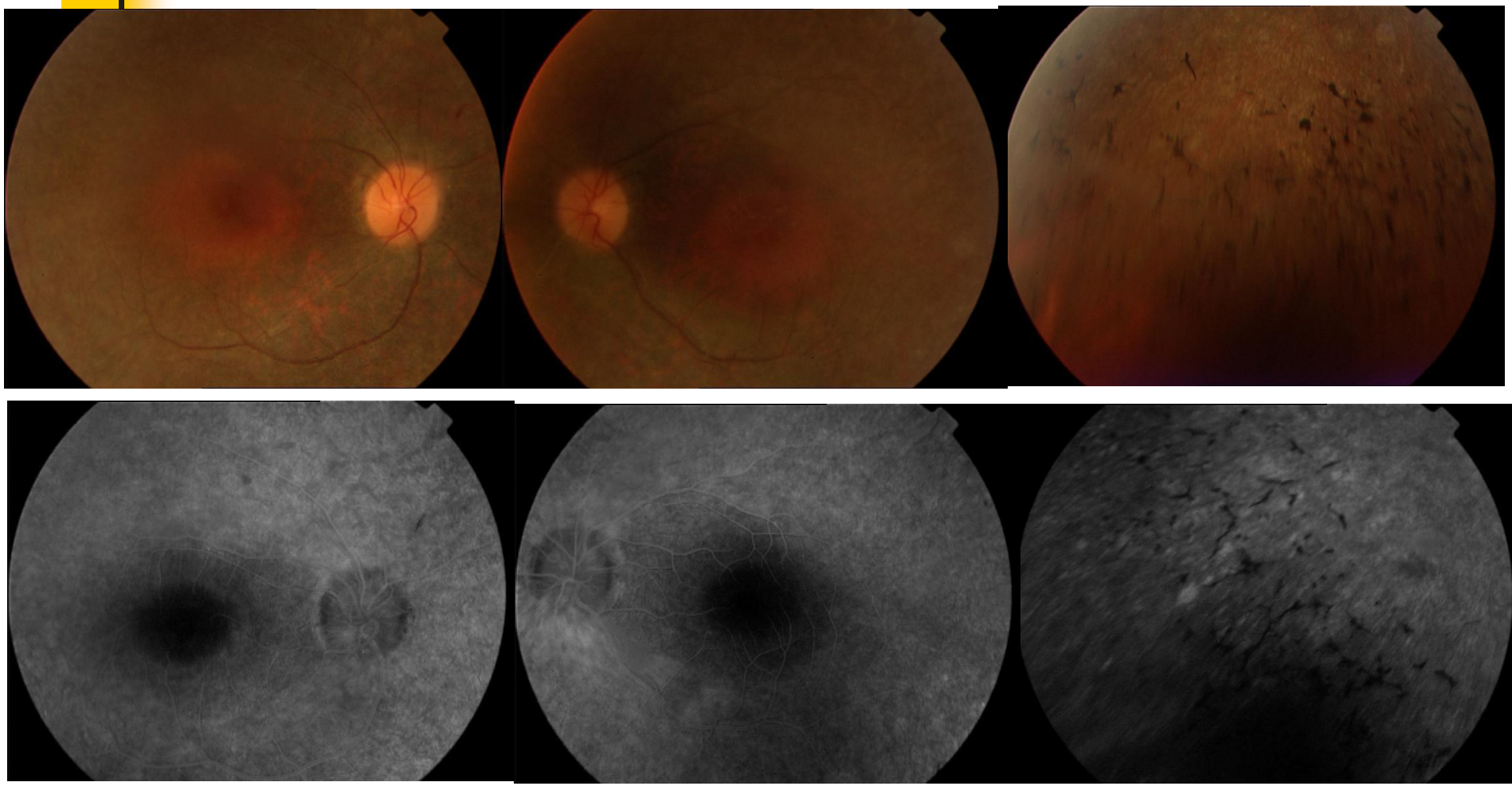

Otozomal dominant RP

X’e bağlı resesif RP

- 35y, E, 10 yıldır görme azlığı
- Gece görme sorunu (çocukluk yıllarından)
- Soygeçmiş: Dedede (annenin babası) benzer sorun.

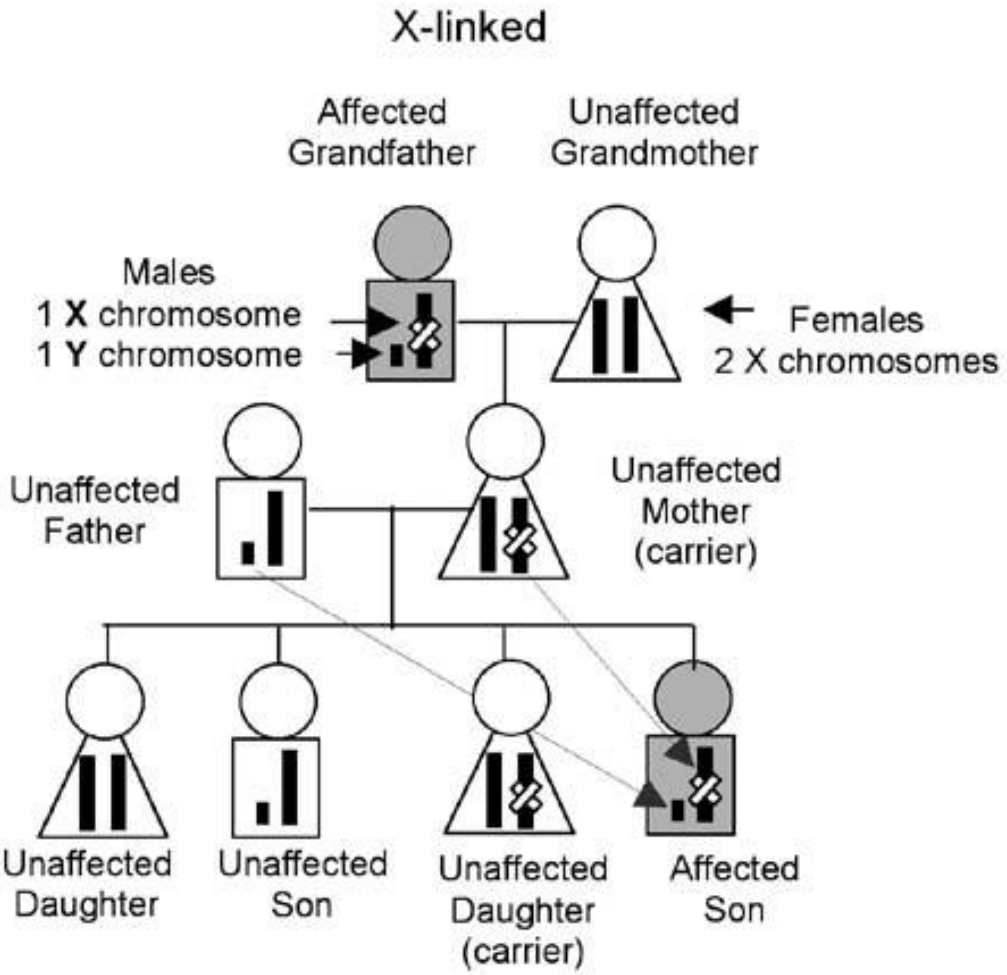
X-linked
Affected Grandfather
Unaffected Grandmother
Males
1 X chromosome
1 Y chromosome
Females
2 X chromosomes
Unaffected Father
Unaffected Mother (carrier)
Unaffected Daughter
Unaffected Son
Unaffected Daughter (carrier)
Affected Son

OR: -6.50 +1.00 x 90 /-5.00 +2.00 x80

GK: 30cmps/ 1/2mps

Bio: PSKK

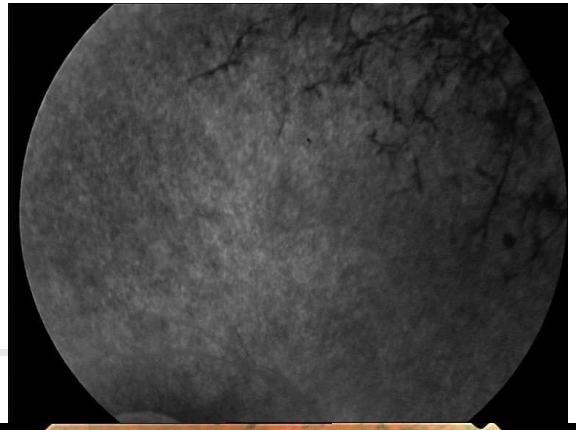

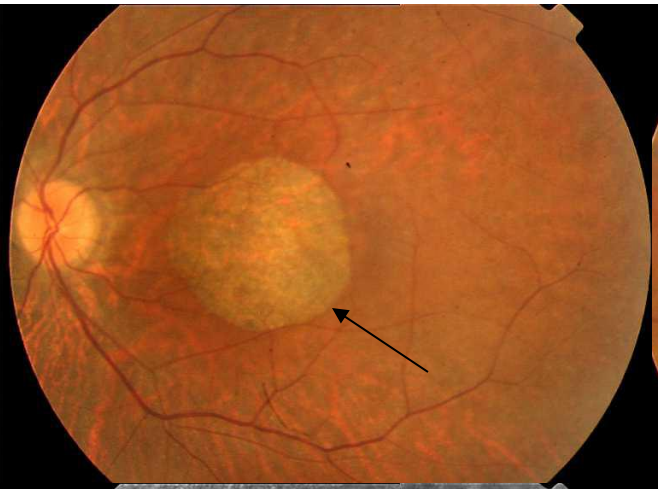

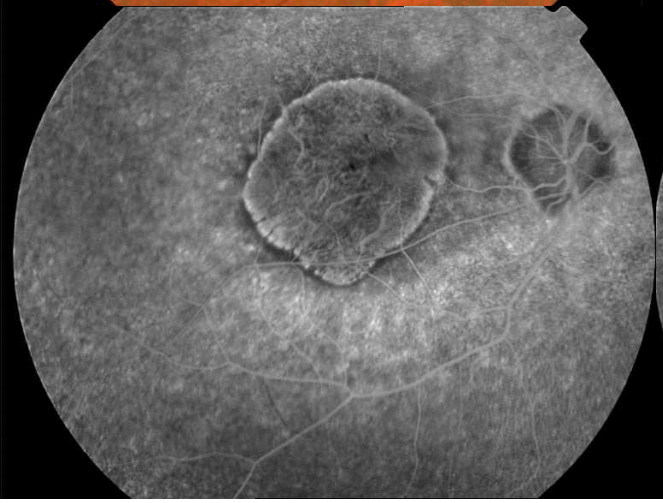

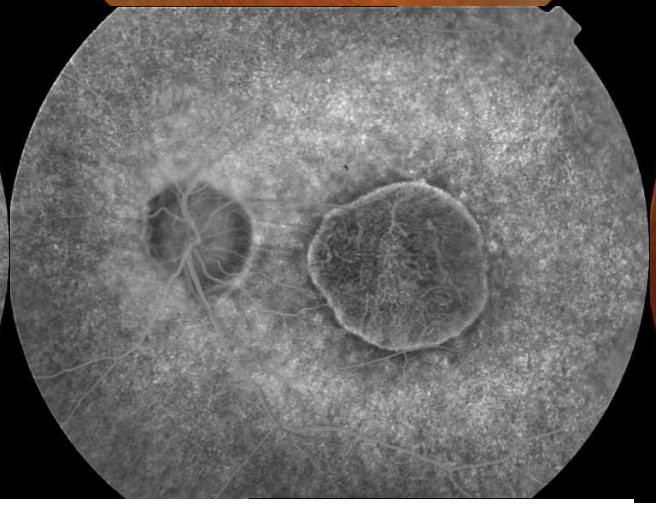

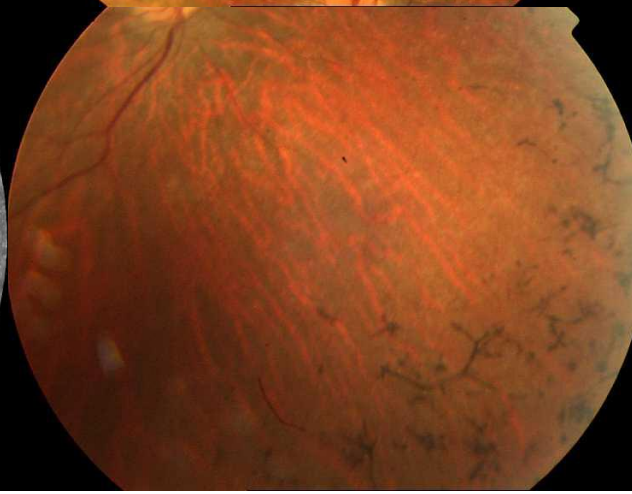

OCT

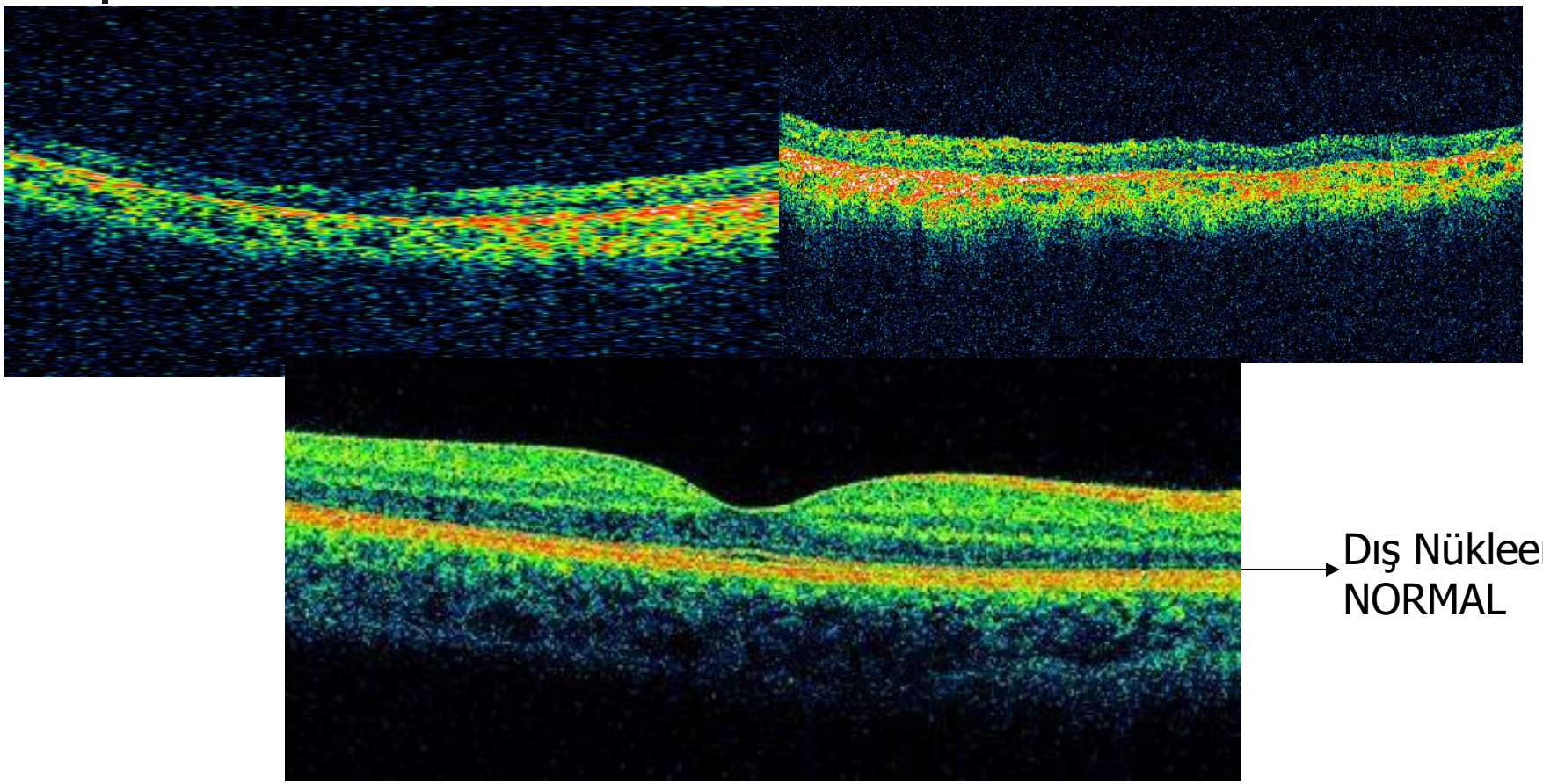

Dış Nükleer T.
NORMAL

Leber'in Konjenital Amarozu (LCA)

- AR geçiş
- Doğuştan gece körlüğü, ciddi görme kaybı (infant)
- Nistagmus, şaşılık, PSK Katarakt,
- Y. hipermetropi
- Pupilla IR: zayıf, keratokonus (%29)
- Retina: doğal / RP benzeri (daha geç)

- ERG: Düz çizgi (kaydedilemez)
- Ayırıcı Tanı: Albinizm, akromatopsi, mavi koni monokromatizm
- Okülodijital reflex
- 1/3 Mental retard.

Olgu: Eİ, 11y, E

- Özel eğitim için rapor başvurusu
- Doğuştan az görme
- Anne baba akrabalık (+): kuzenler
- Ablada aynı sorun (+) 2 kardeş N

- GK: EH/EH
- Ön segment: Enoftalmik, Nistagmus,
- IR: çok zayıf
- Retinoskopi: +5.00/+6.00 (artmıyor)
- ERG: kaydedilemiyor

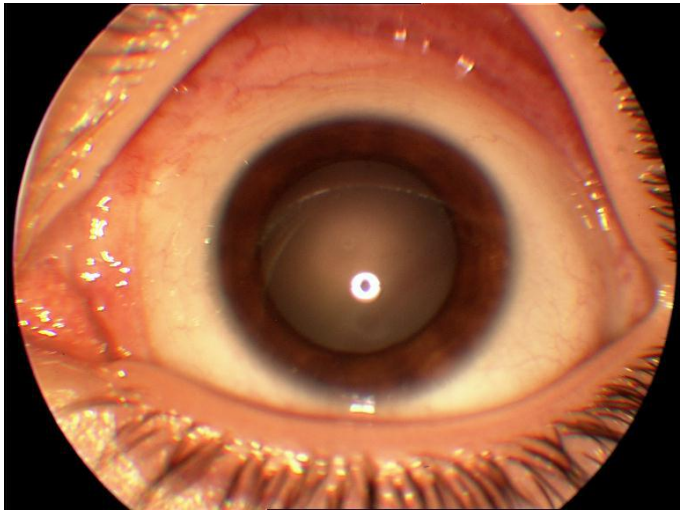

RP varyantları

- RP sine pigmenti
- R. Punctata albesens,
- CSNB (Fundus albipunktatus, Ogushi)
- RP inversus
- Sektörel form, Pigmente paravenöz atrofi
- Coats like RP
- Komplike RP: Sendromik formlar: Usher, Refsum, Bardett Biedel send…

Olgu: 20y, K, Gece körlüğü, Baba ve amcada benzer sorun, Diğer kardeşlerde (-) Anne-Baba (3. akraba)

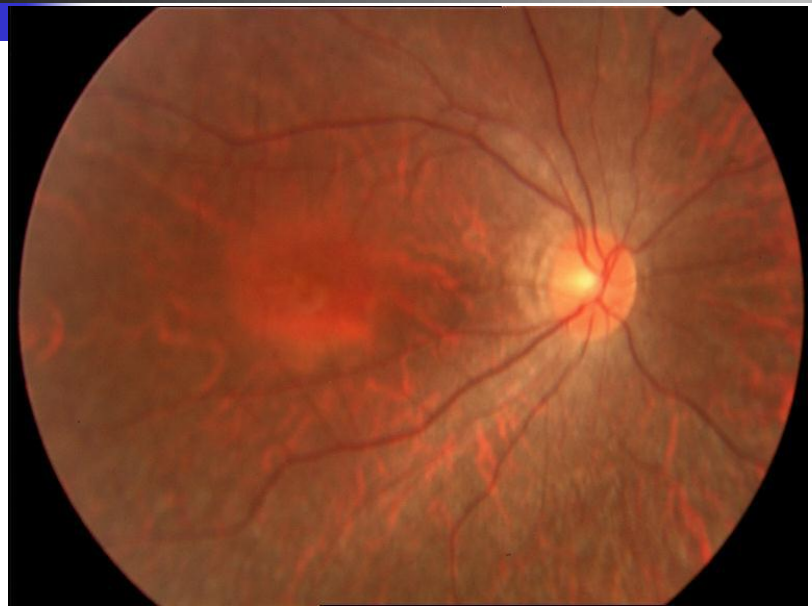

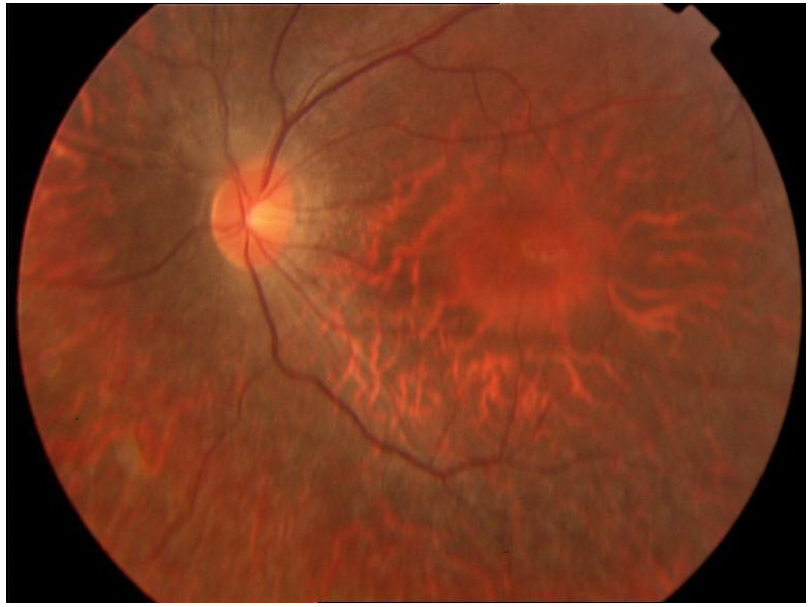

GK: -7.00 -2.00 x 20 (0.7) -7.00 -3.00 x 160 (0.7)

ERG: Belirgin subnormal

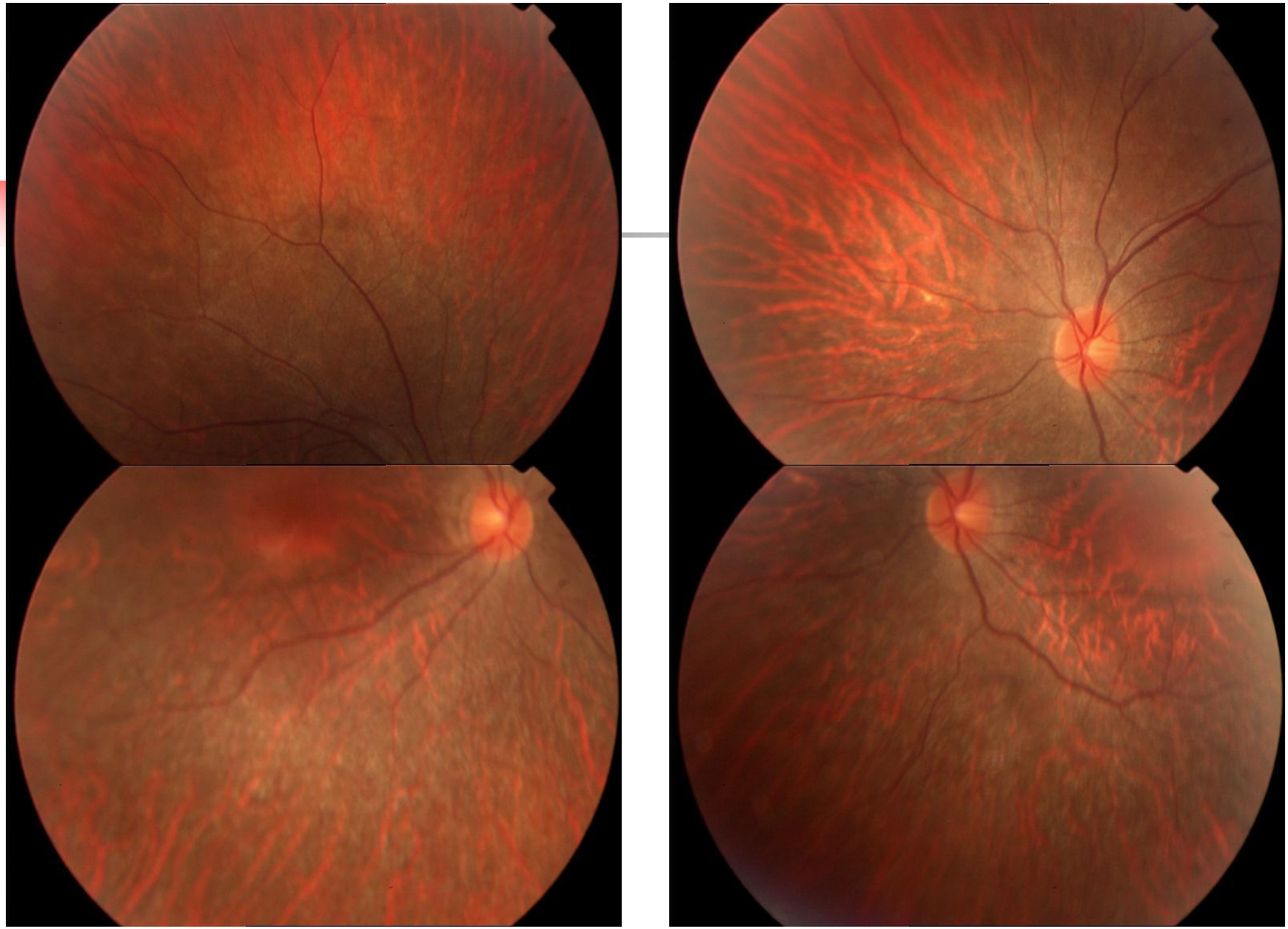

- RP Sine Pigmenti = RP (ADRP) (erken dönem)

RP İNVERSUS (24y E, GK: 1mps)

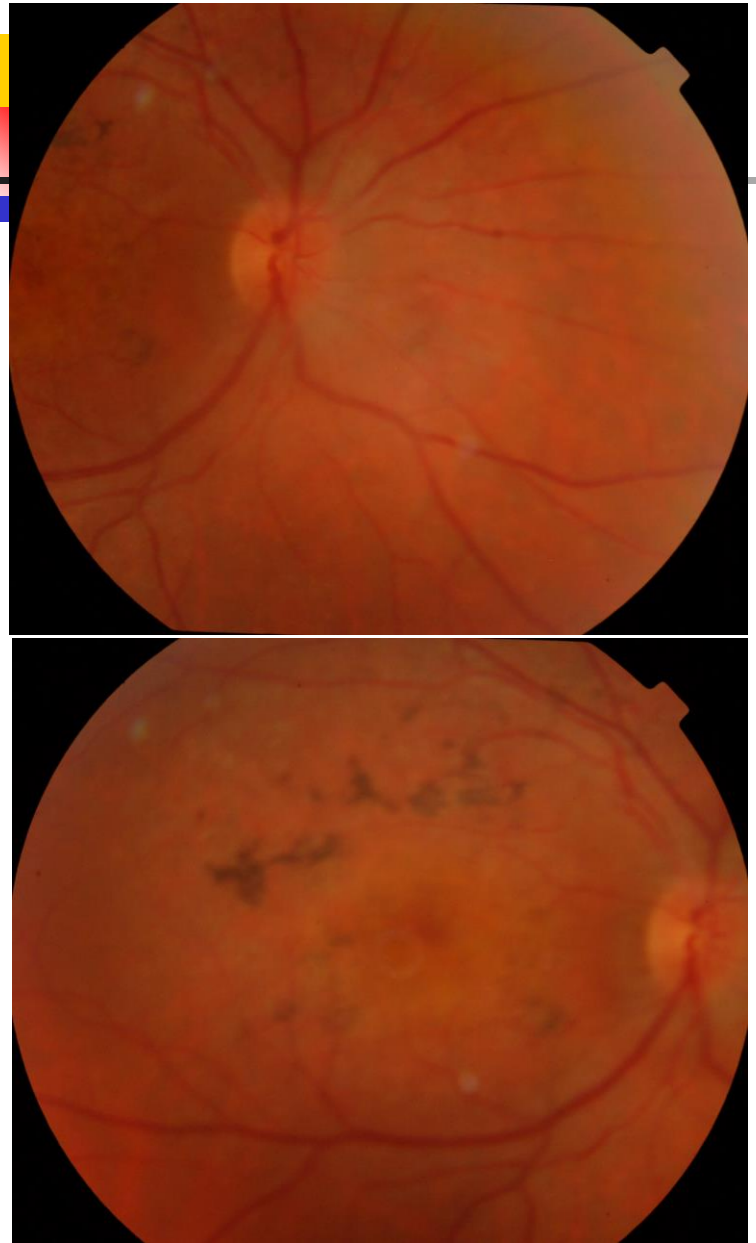

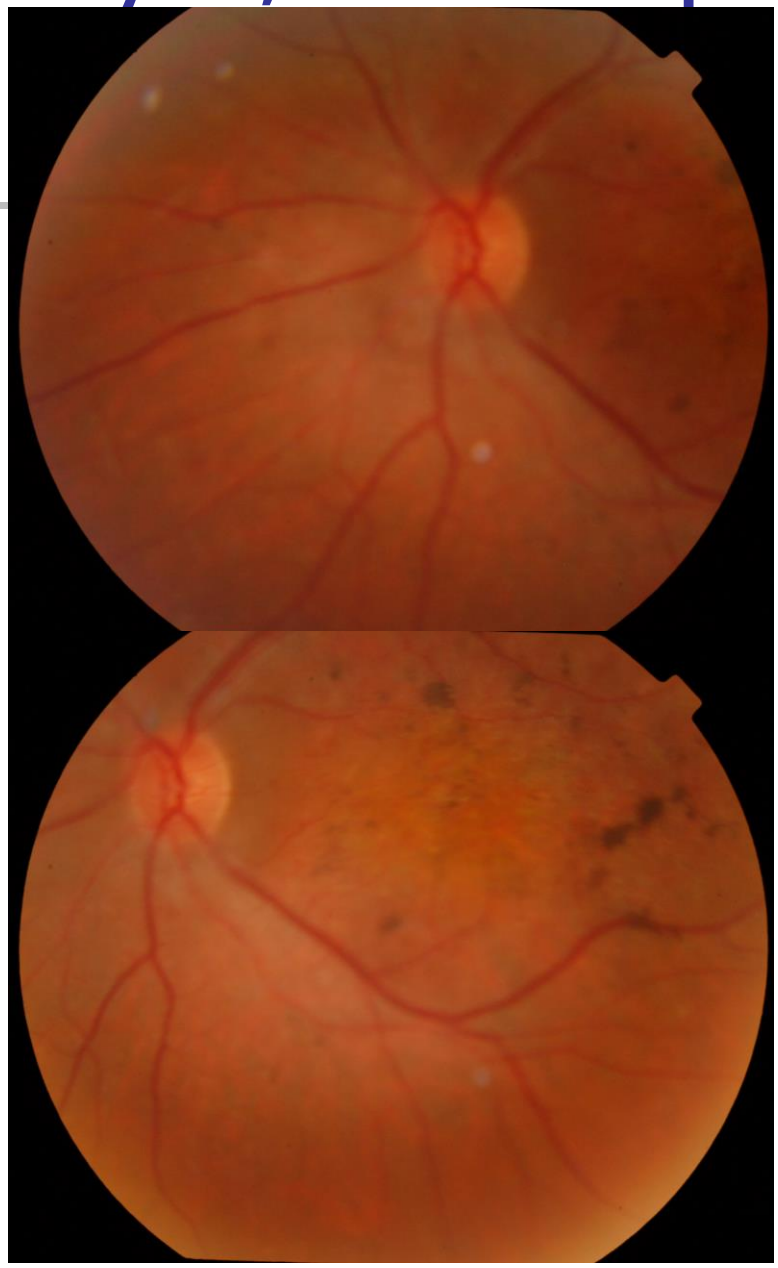

29y ağabey, GK: 1/2mps,
Pigmente Paravenöz Retinokoroidal Atrofi

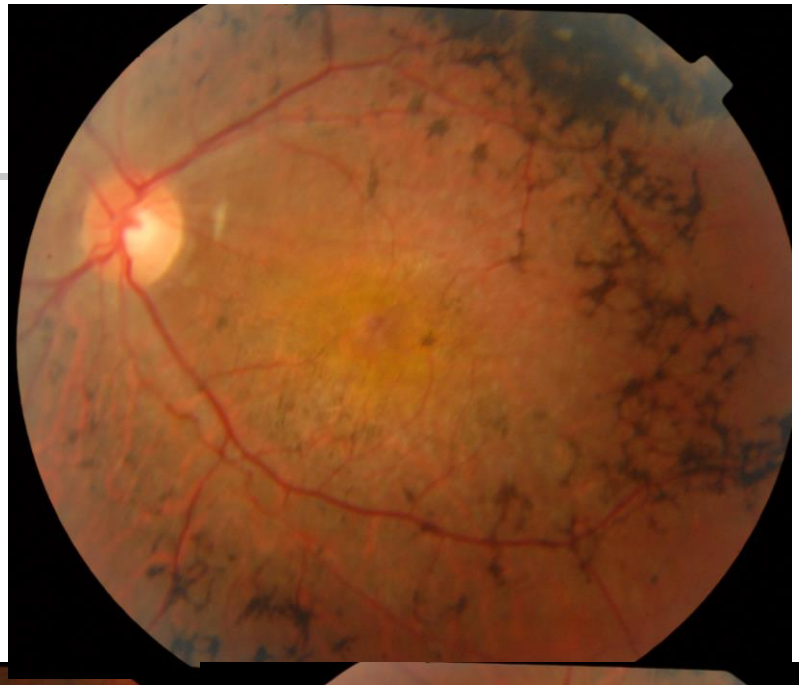

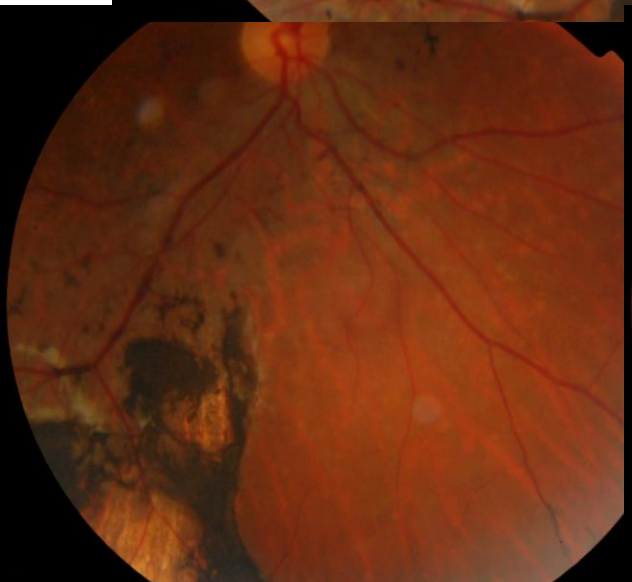

Pigmente paravenöz retinokoroidal atrofi

- Inflammatory pigmented paravenous retinochoroidal atrophy. Batioglu F, et al. Eye, 2002.

- Pigmented paravenous retinochoroidal atrophy. A literature review supported by seven cases. Kükner AS, et al. Ophthalmologica. 2003. (7 olgu)

Yavaş progresyon: RP benzeri tablo

47y, K, sol göz 10 yıldır az görüyor.
1ay önce soldan kat op, sonrasında RD için sevkli, Gece görme az, Aile hik (çok bireyde +),

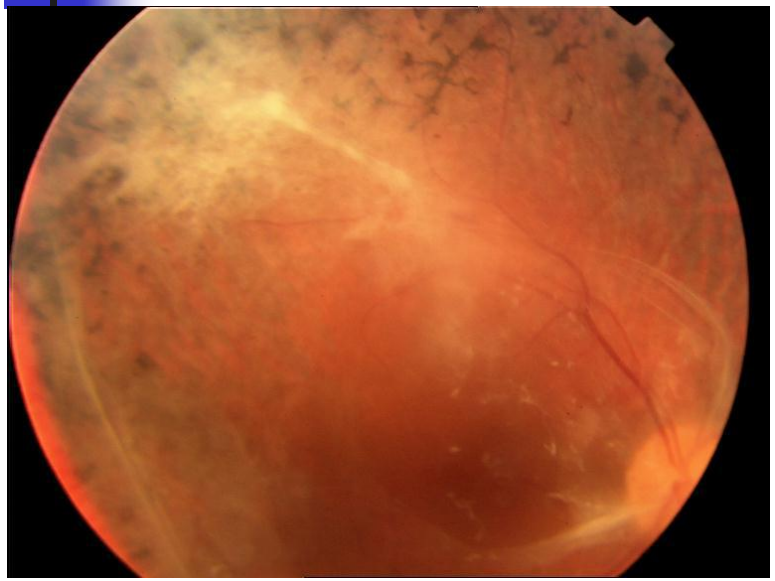

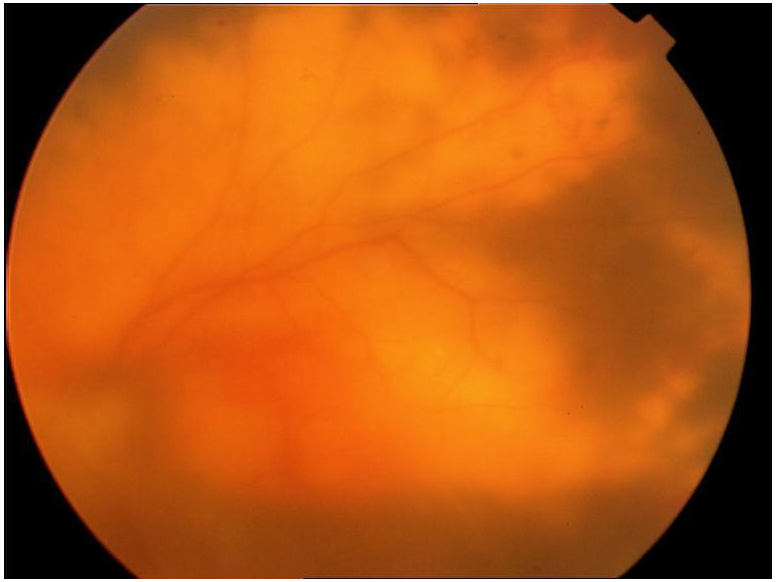

GK: 0.1/EH, TO: 15/32 (App), Sol: RI(+) Kornea ödemli

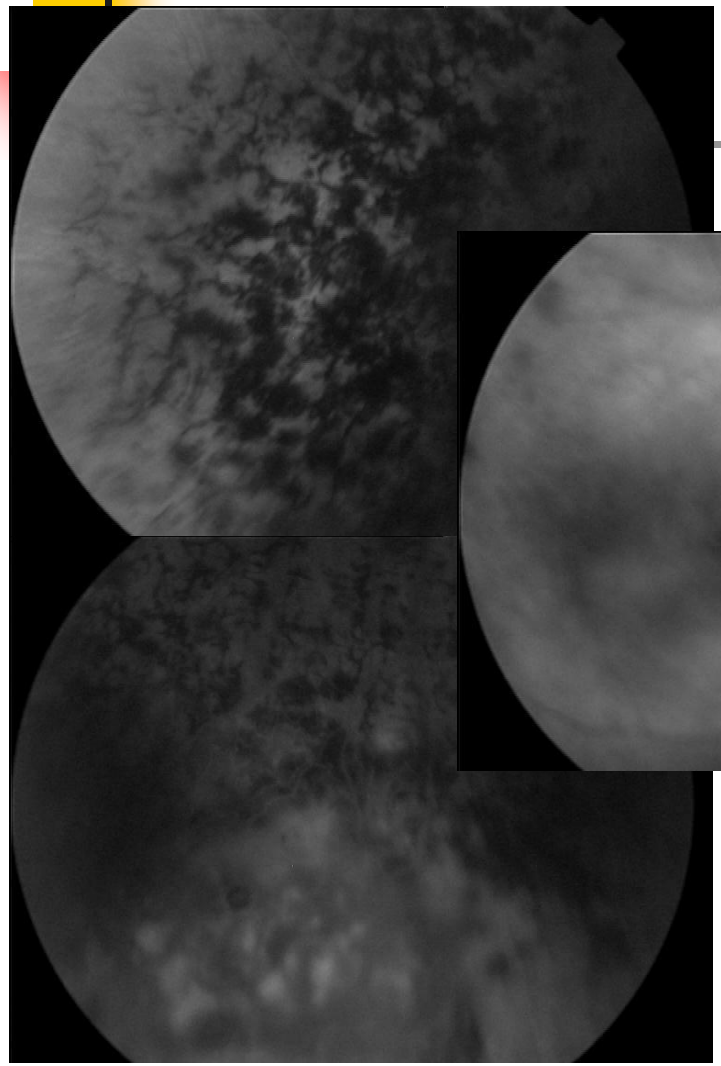

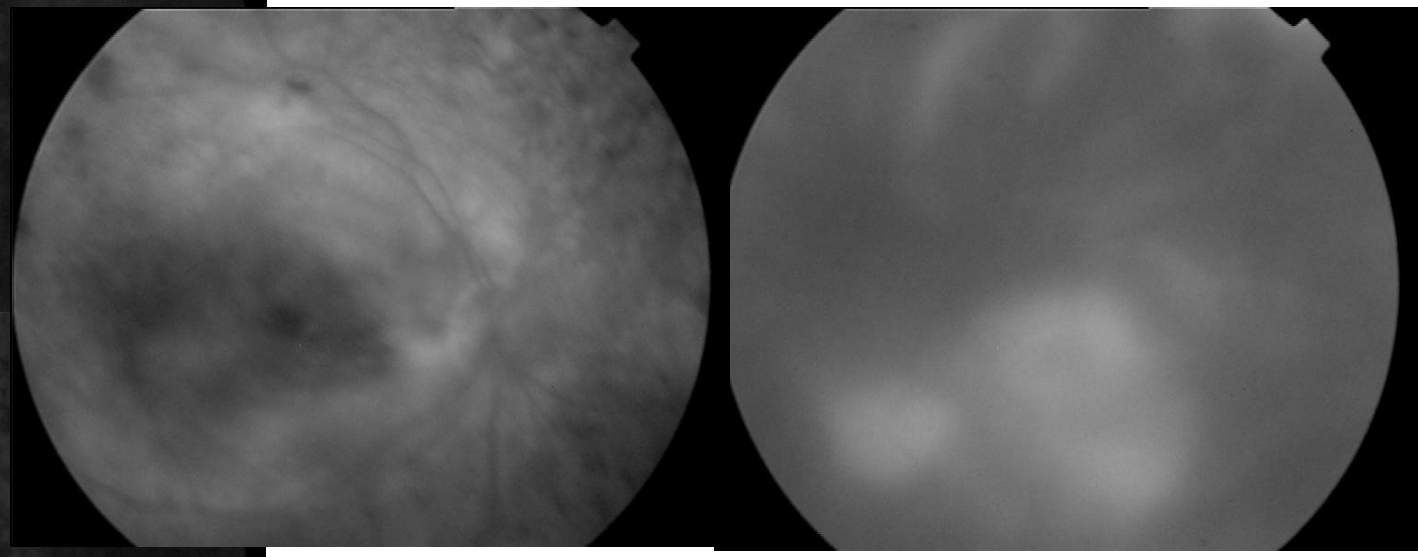

ERG: Sağ: belirgin subnormal, sol kaydedilemedi

Coats like RP

- RP: %3.6

- SOL: KRIO+Siklokrio (Mayıs 2003)
- SAĞ: Laser FK

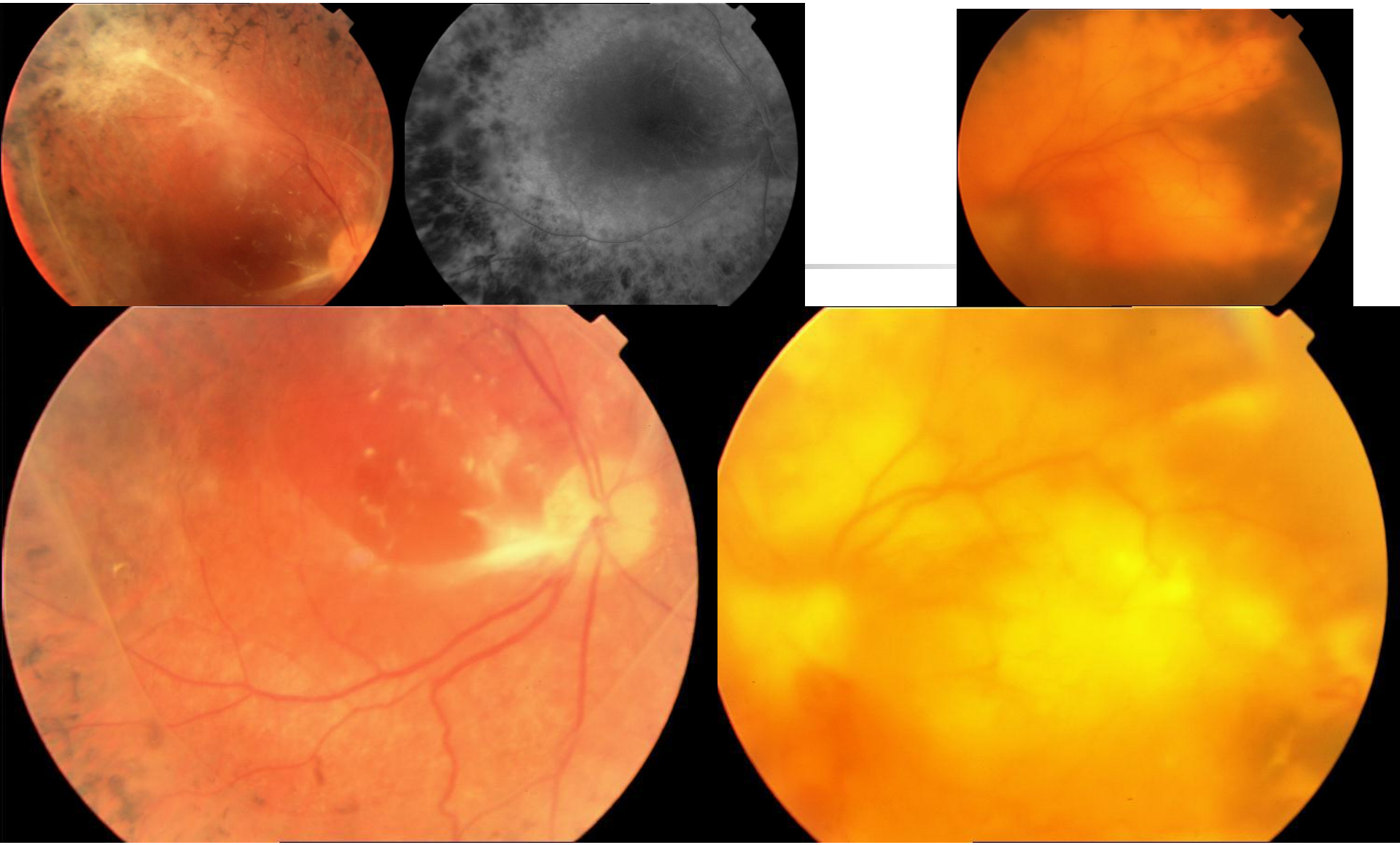

GK: 0.2 / EH TO: 14/20 (ilaçsız), RI(-) (Nisan 2004)

- Ozdek S ve ark. Coats'-like retinitis pigmentosa variant and nanophthalmos. Can J Ophthalmol. 2007 Dec;42(6):877-8.

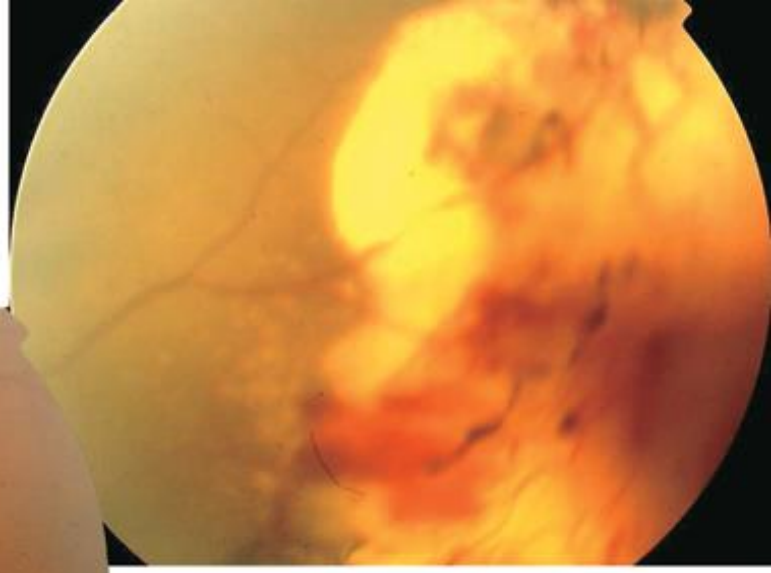

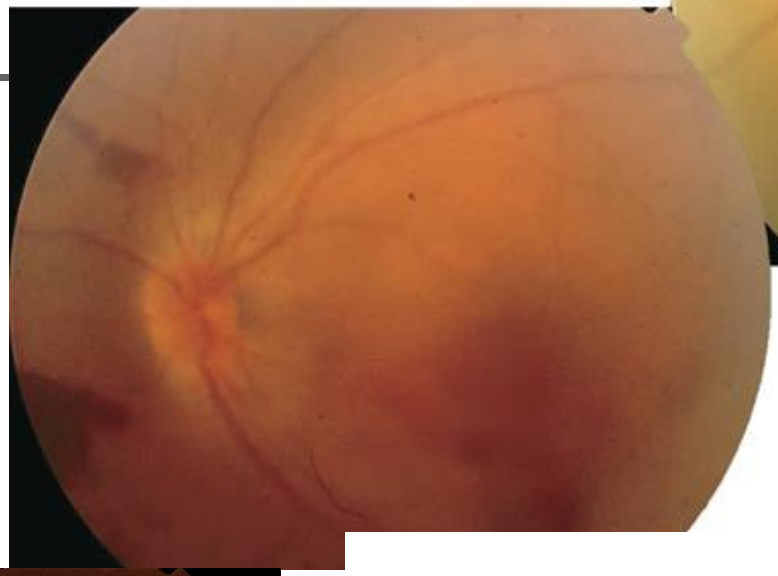

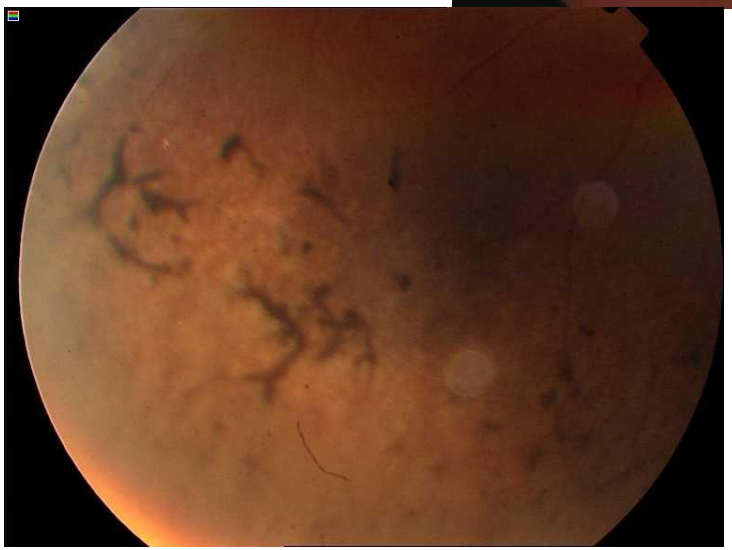

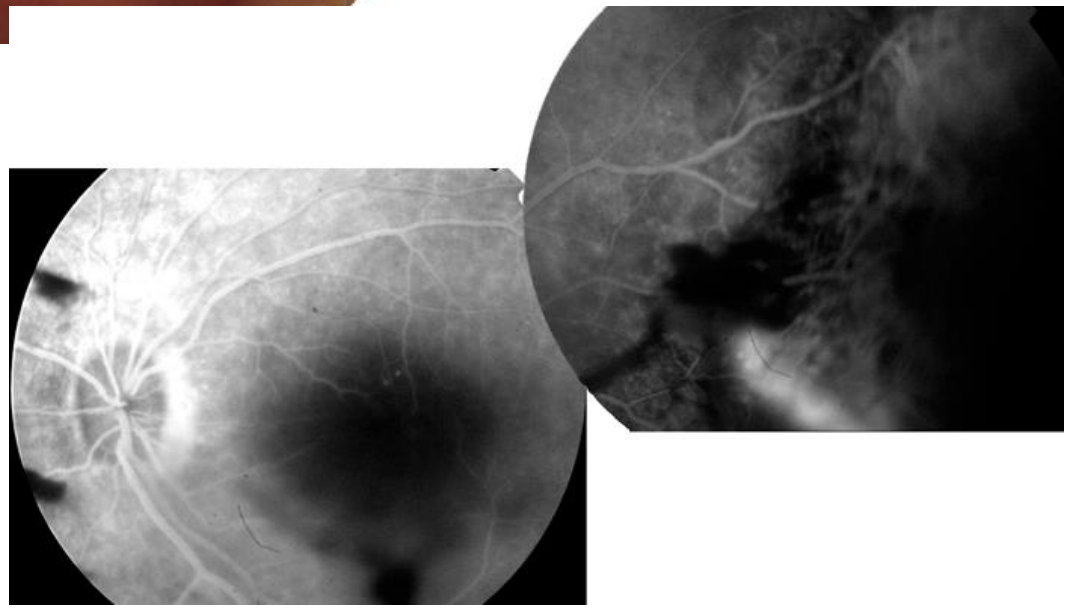

Sendromik formlar

- Usher Send: İşitme kaybı + RP
- Tüm RP'lerin %18'i

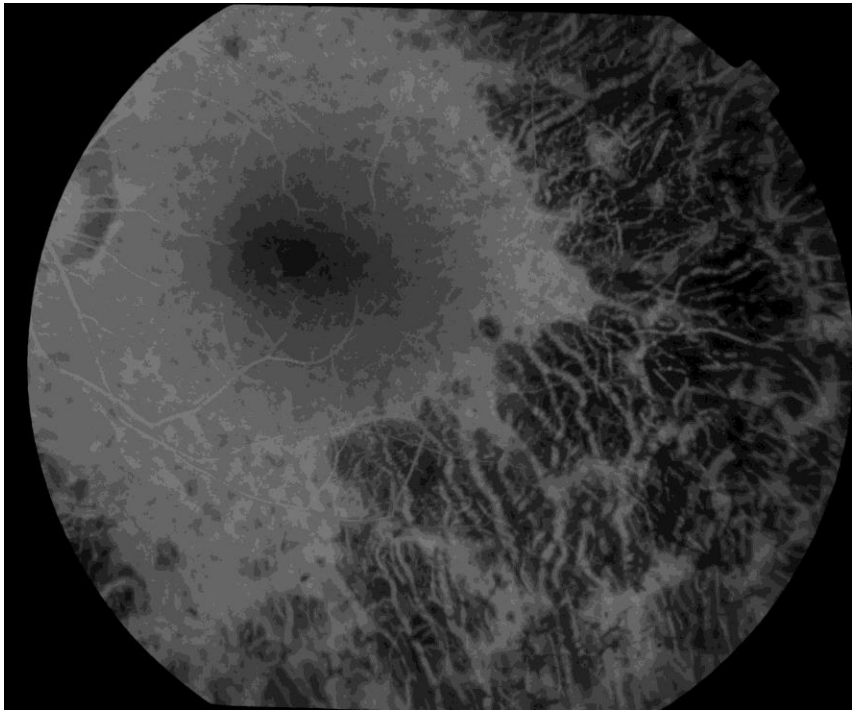

Olgu: 9y, K, Nistagmus, gece görme↓, Polidaktili, Obesite, G: 0.3/0.3, (-3.00 -2.00x180)

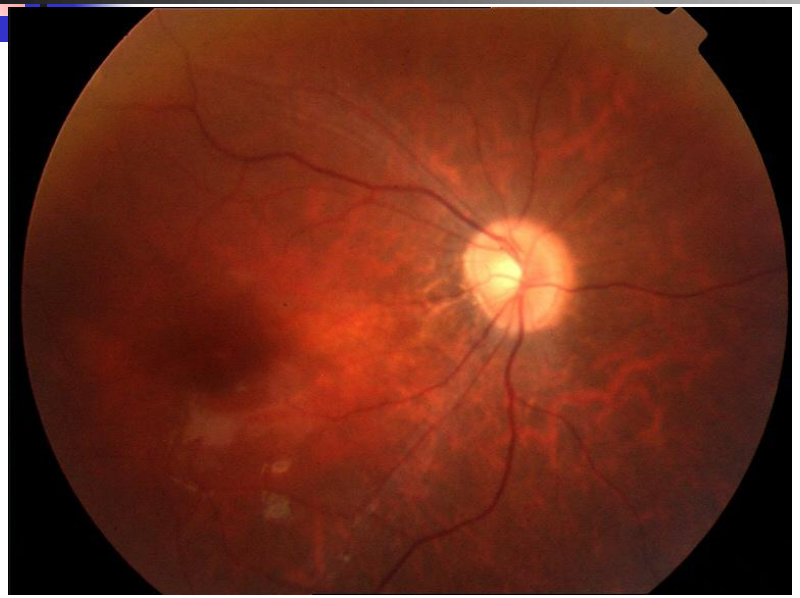

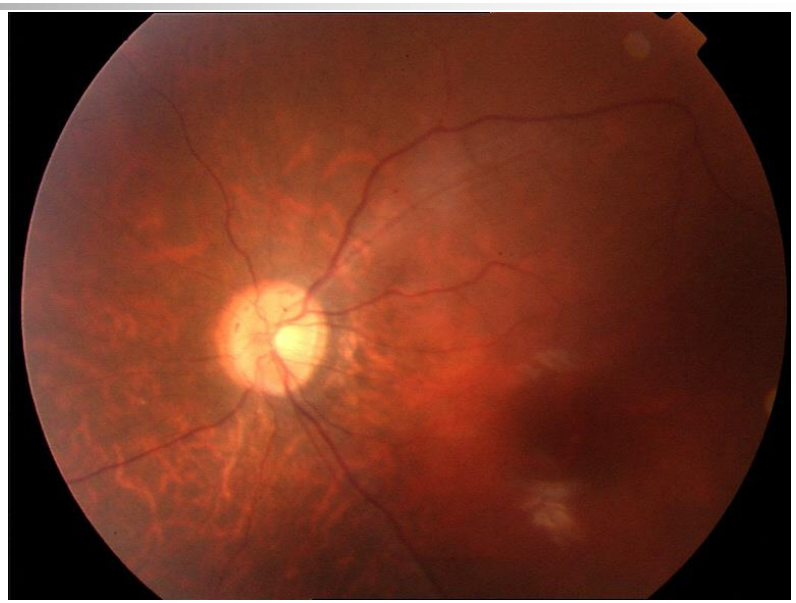

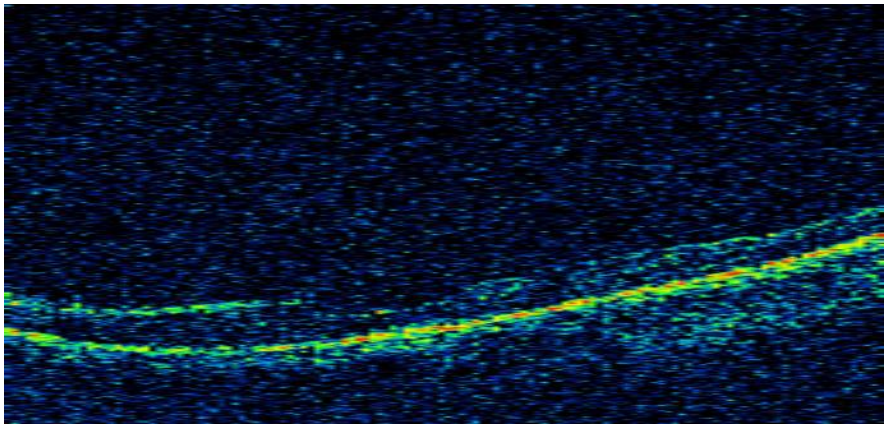

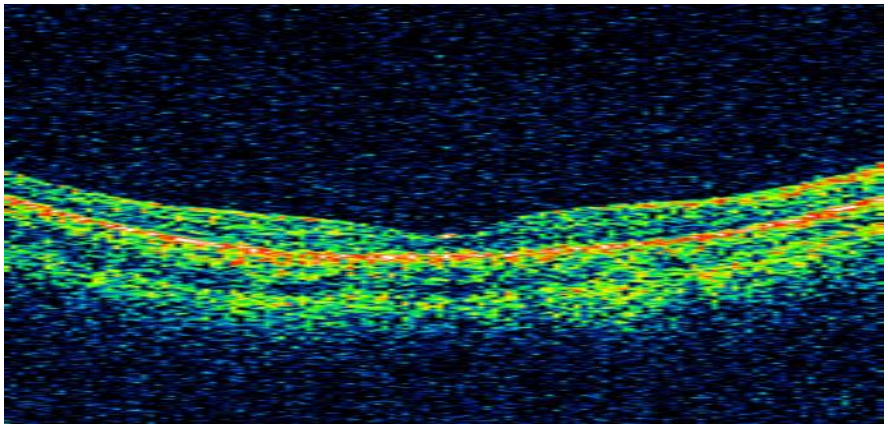

Bardet-Biedl Sendromu

- Polidaktili
- Obesite
- Retinopati
- ERG: skotopik amplitüdlerde ciddi ↓
- Görme alanı: Küçük adacıklar hariç total absolü skotom

Retinitis Punctata Albesens

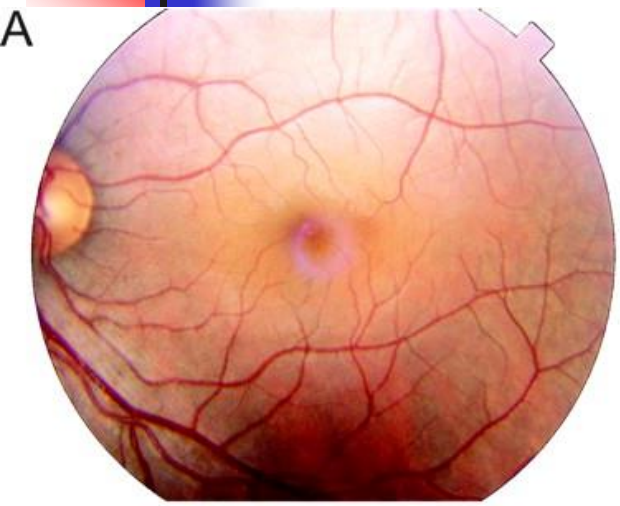

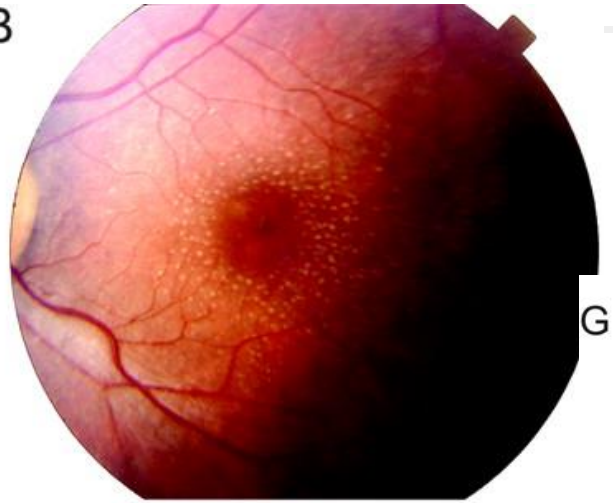

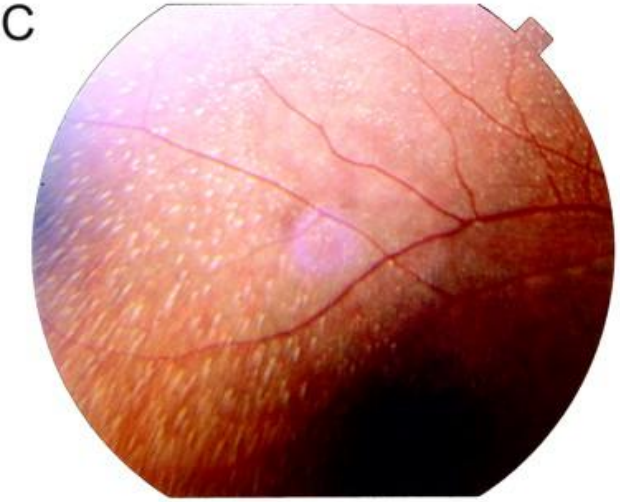

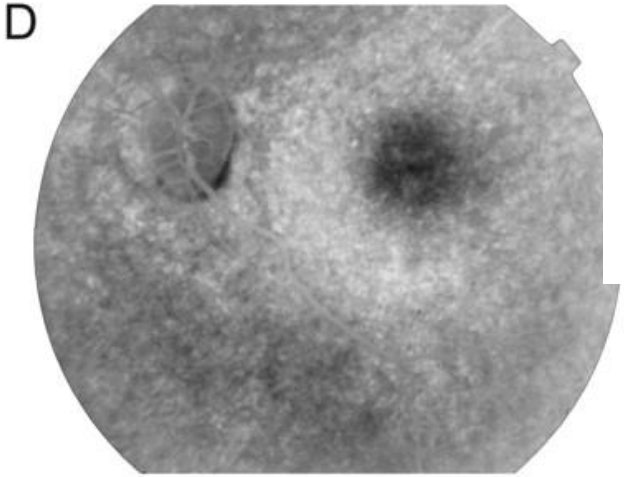

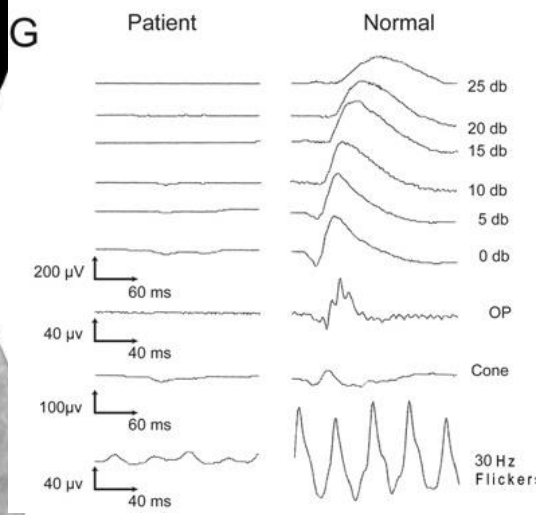

Fundus Albipunktatus

- Konjenital ilerlemeyen gece körlüğü (CSNB)
- ERG: 30 dak karanlık adaptasyonunda cevap (-)
- 4 saat adaptasyonda (+)

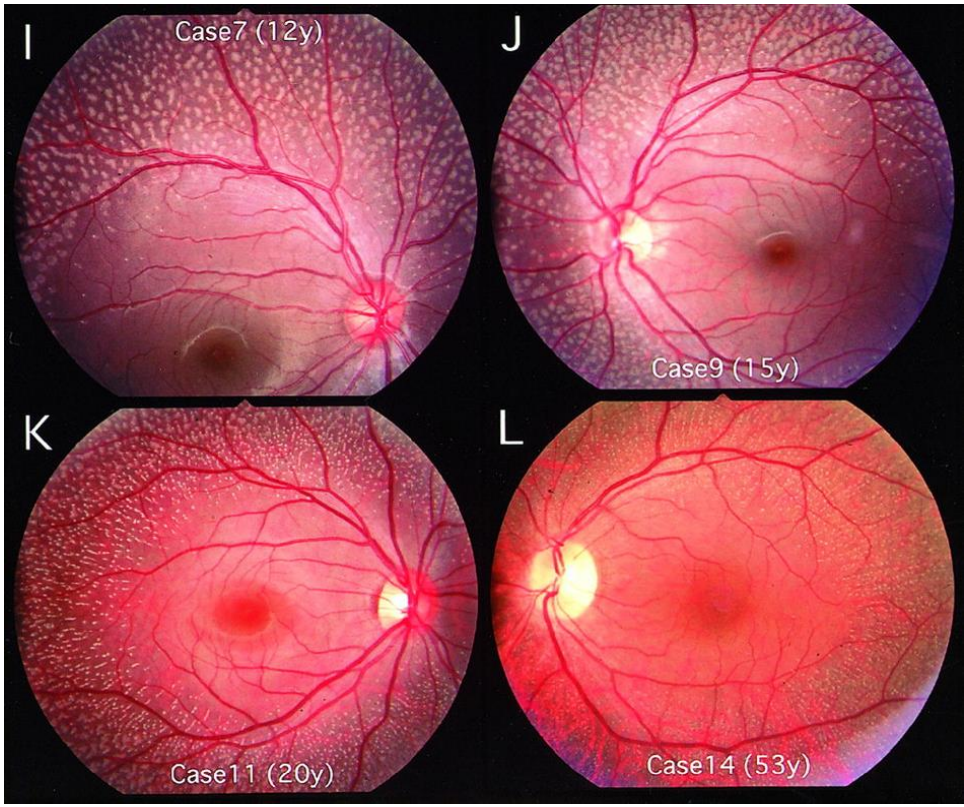

Psödoretinitis Pigmentoza

- Sifiliz
- Travmatik retinopati
- DUSN
- CAR, MAR,
- İlaç toksisitesi
- Rubella retinopati

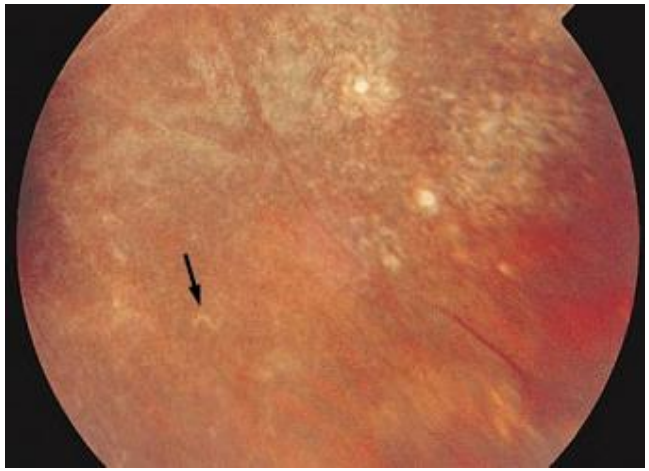

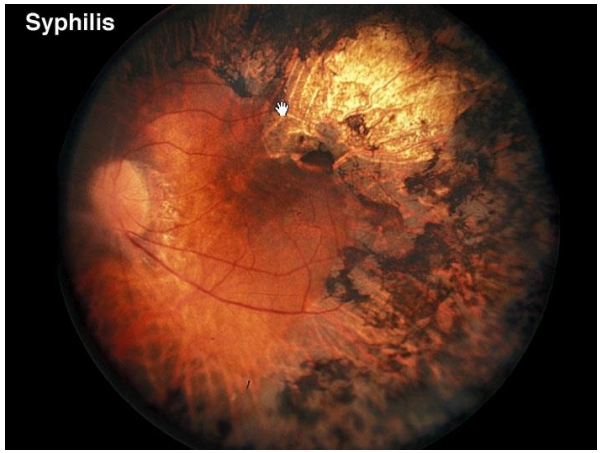

50y, GK: 20/20, DM(+) FTA-Abs (+)

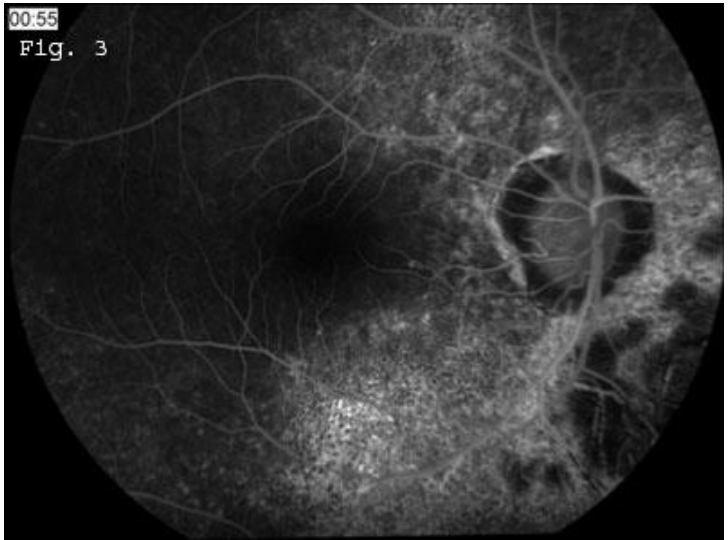

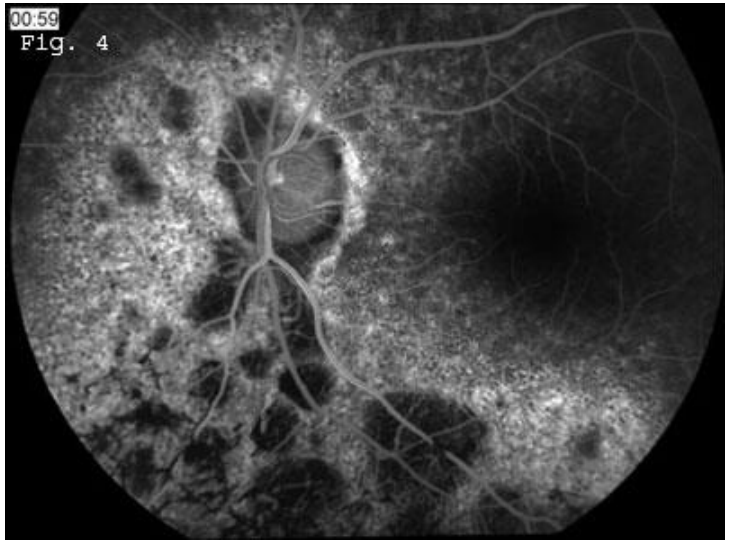

Psödo-RP-Travma

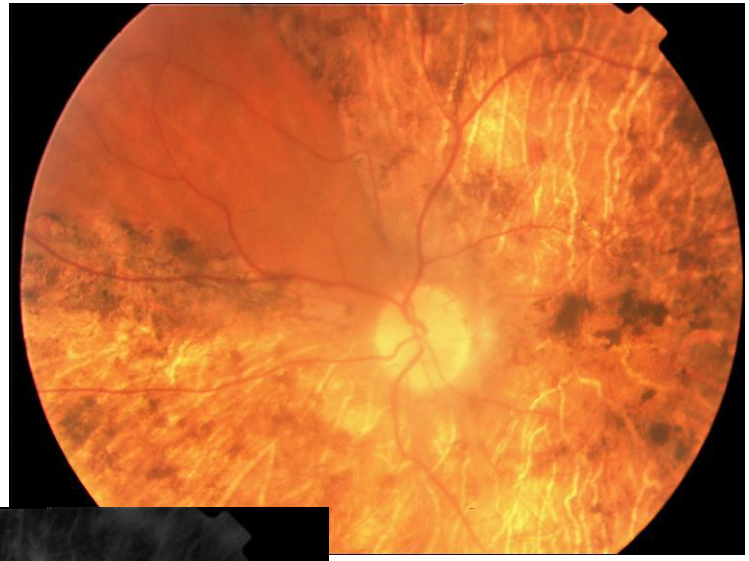

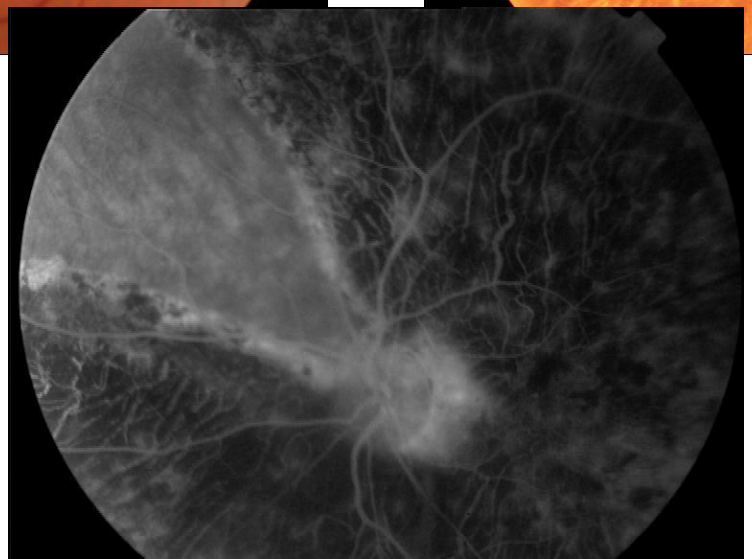

GK: Tam/ 20cmps
RAPD(+)
ERG: Solda belirgin ↓

KONİ DİSTROFİ
KONİ ROD DİSTROFİSİ

- Progresif santral görme kaybı
- Renkli görmenin bozulması, fotofobi
- ERG de Kon cevabında ciddi kayıp
- Oftalmoskopi: Santral atrofi
- Zamanla rod fonksiyonlarında kayıp..

ERG

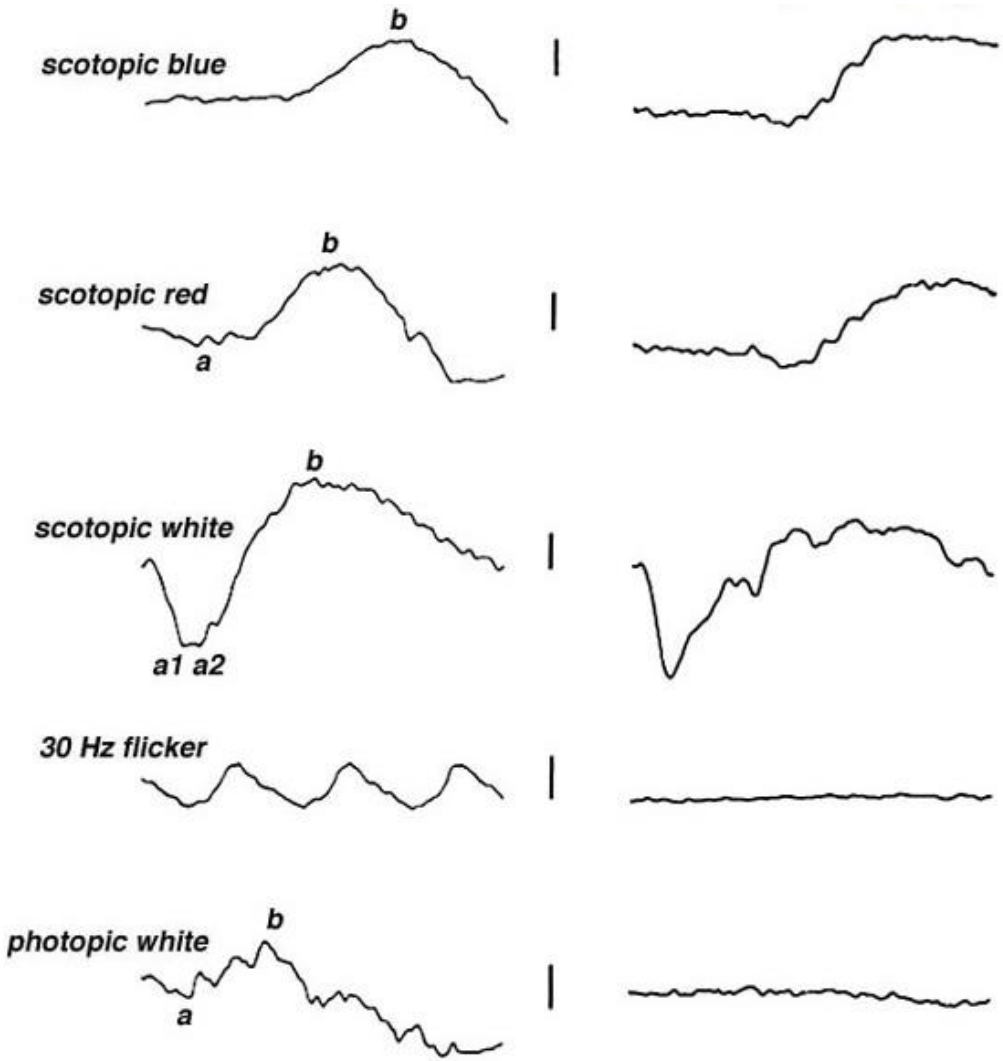
scotopic blue
b
scotopic red
b
a
scotopic white
b
a1 a2
30 Hz flicker
photopic white
b
a

Olgu: 37y, E

- Görmede azalma, ışıktan rahatsız olma
- Renk ayrımı zor, Geceleri rahat
- Aile hikayesi: Yeğeninde RP (+)
- Anne baba: kuzenler

GK: K. Myopik ast 0.3/ 0.3, Renkli G: (-)

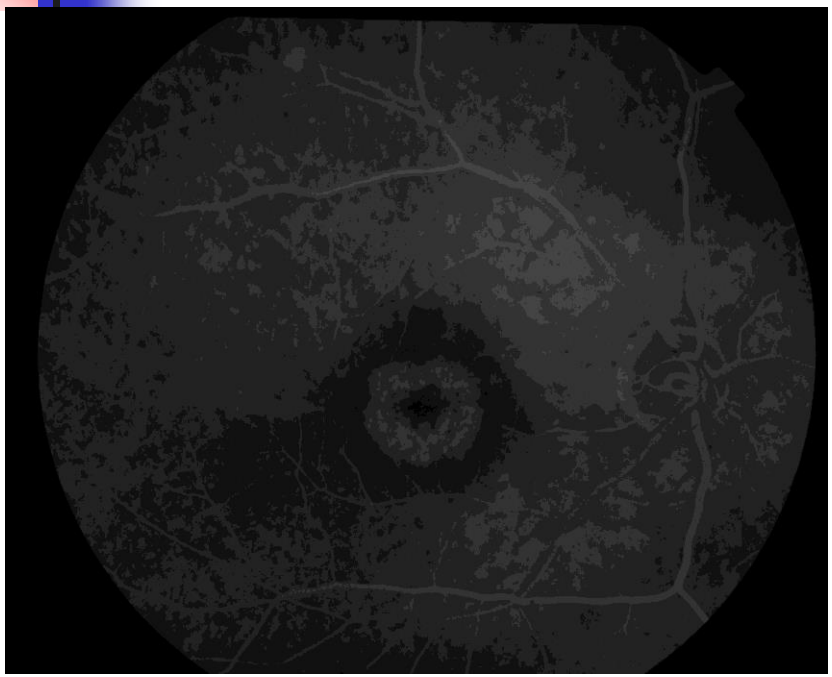



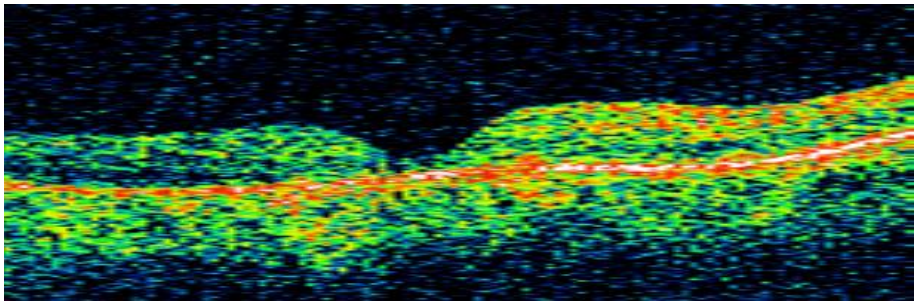

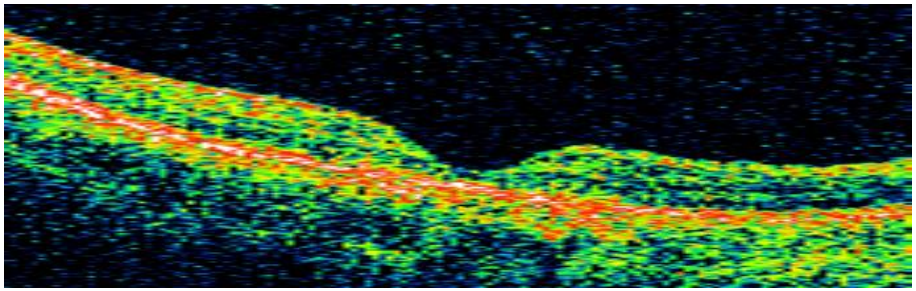

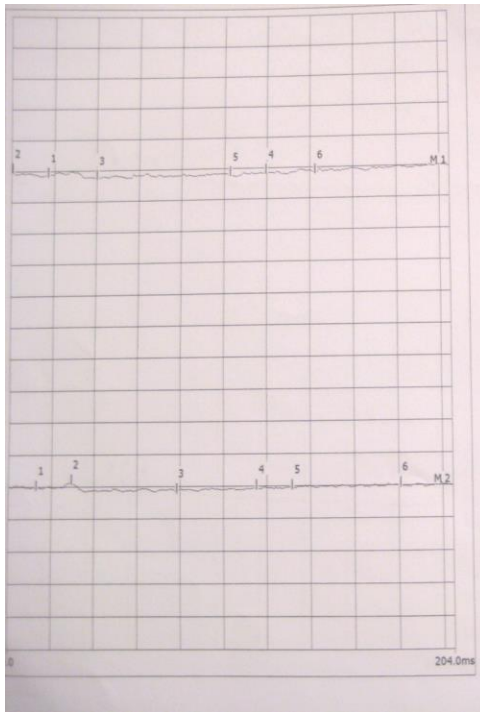

Patient: senturk sahin

Code: 171334

Exam: ERG - CONE RESPONSE (ISCEV)

Date: 08/09/200

Peak Time (m

Amplitude (µV)

	1	2	3	4	5	6	1	2	3	4
M 1	-15.38	0.000	-25.39	-15.62	-20.75	-18.07	16.61	0.000	39.45	118
	15.38	25.39	9.766	5.127	2.686		16.61	39.45	79.17	
M 2	-6.470	11.96	-17.70	-6.836	-7.446	-2.563	12.35	28.69	77.70	114
	18.43	29.66	10.86	0.610	4.883		16.34	49.01	36.66	

Cevap yok

Labels:

M 1 Cone Response LEFT EYE

M 2 Cone Response RIGHT EYE

Notes - Diagnosis:

rod kon distrofisi

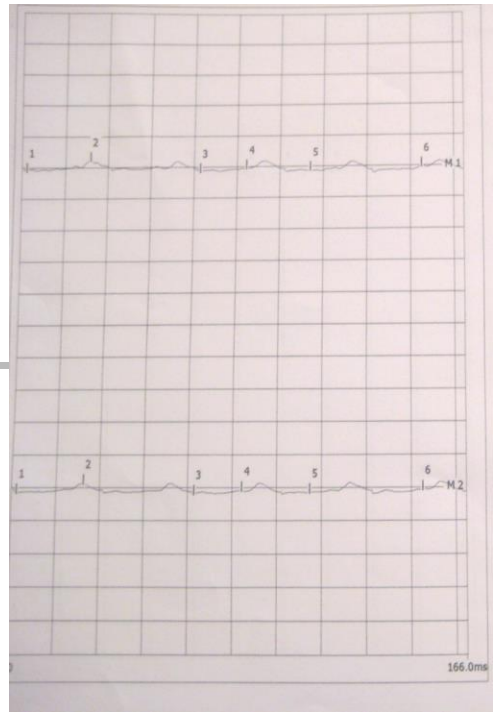

Patient: senturk sahin

Code: 171334

Exam: ERG - 30 HZ FLICKER (ISCEV)

Date: 08/09/20

Peak Time

Amplitude (µV)

	1	2	3	4	5	6	1	2	3
M 1	-11.23	23.44	-15.01	-4.761	-12.57	-2.197	1.297	25.29	66.79
	34.67	38.45	10.25	7.812	10.38		23.99	41.50	17.51
M 2	-15.38	13.06	-19.53	-9.033	-15.26	-6.958	1.297	25.94	66.79
	28.44	32.59	10.50	6.226	8.301		24.64	40.85	17.51

flicker yanıtı azalmış

Labels:

M 1 30 Hz Flicker LEFT EYE

M 2 30 Hz Flicker RIGHT EYE

Notes - Diagnosis:

rod kon distrofisi

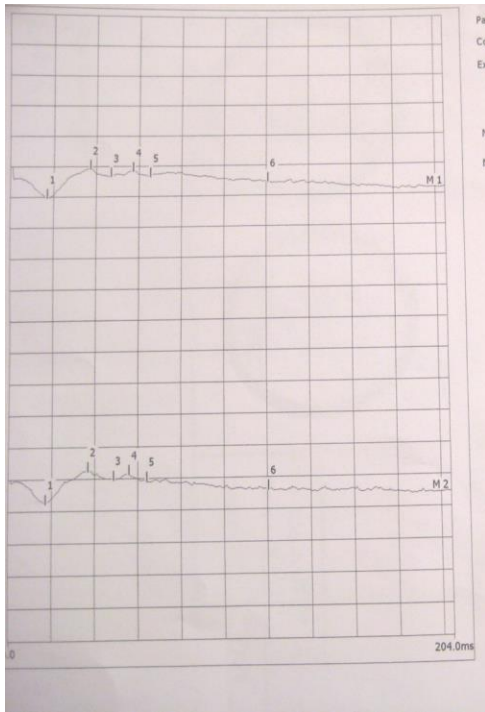

Patient: senturk sahin

Code: 171334

Exam: ERG - ROD RESPONSE (ISCEV)

Date: 08/09/2009

Peak Time (ms)

Amplitude (µV)

	1	2	3	4	5	6	1	2	3	4
M 1	-101.1	-6.104	-32.10	-14.04	-32.35	-51.88	16.61	36.55	46.22	56.49
	94.97	26.00	18.07	18.31	19.53		19.94	9.667	10.27	8.156
M 2	-74.71	25.88	-2.563	14.28	-6.958	-37.60	16.73	36.26	48.03	55.28
	100.6	28.44	16.85	21.24	30.64		19.52	11.77	7.250	8.156

b dalga amplitüdünde azal

Labels:

M 1 Rod Response LEFT EYE

M 2 Rod Response RIGHT EYE

Notes - Diagnosis:

kon rod distrofisi

- Başlangıç yaşı değişken
  - Çocukluk veya erken yetişkin dönem
- GK: <20/200

KORD

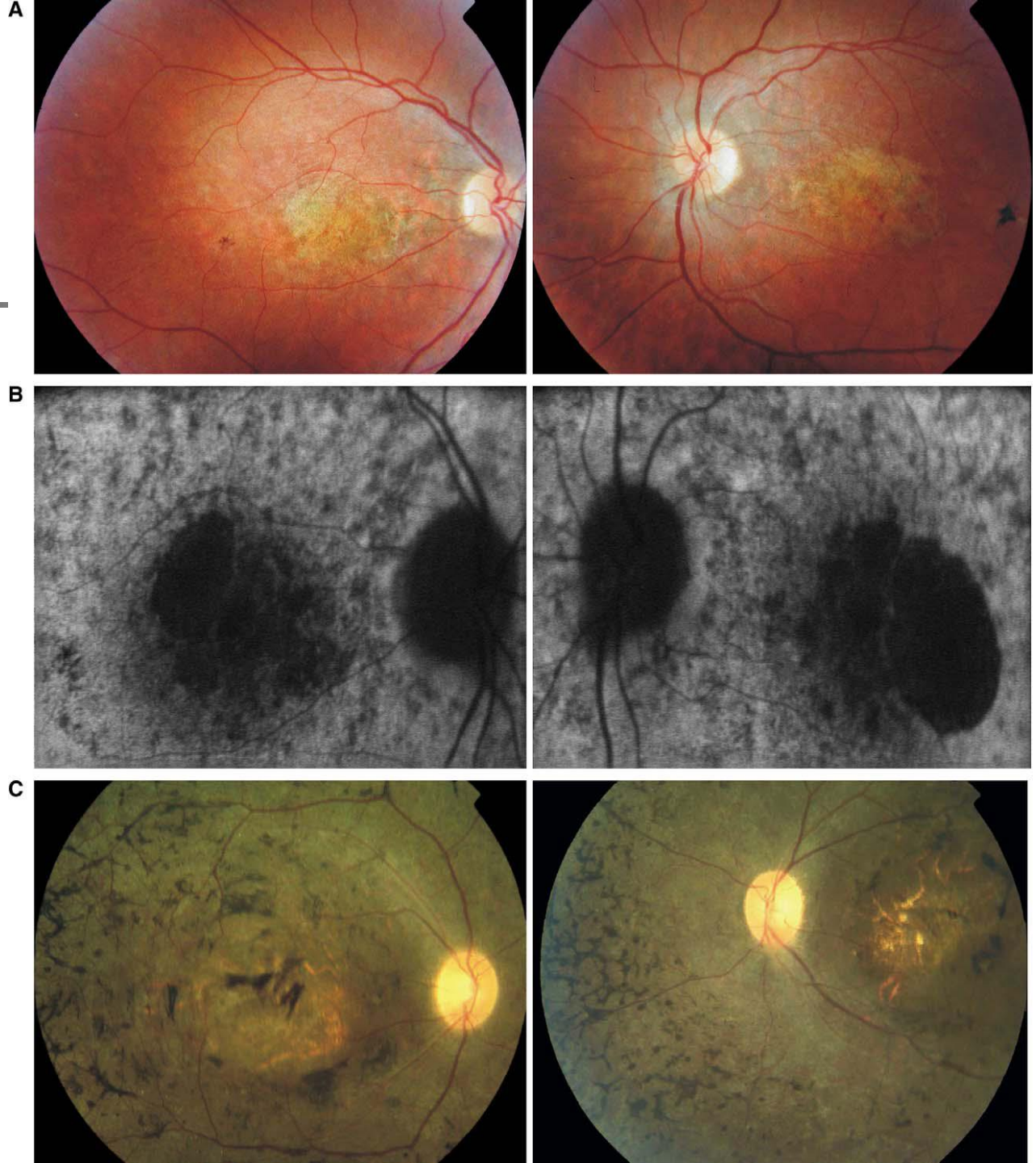

Olgu

- 21y K, 15 yıldır bilat görme azlığı
- Gece gündüz fark yok, 2 erkek kardeşte gece körlüğü (+)

- Özdek S, ve ark. Stargardt's disease and retinitis pigmentosa: Different phenotypic presentations in the same family. Eye, 2005, Nov;19(11):1222-5

GK: 20/400 (Sağ-Sol)

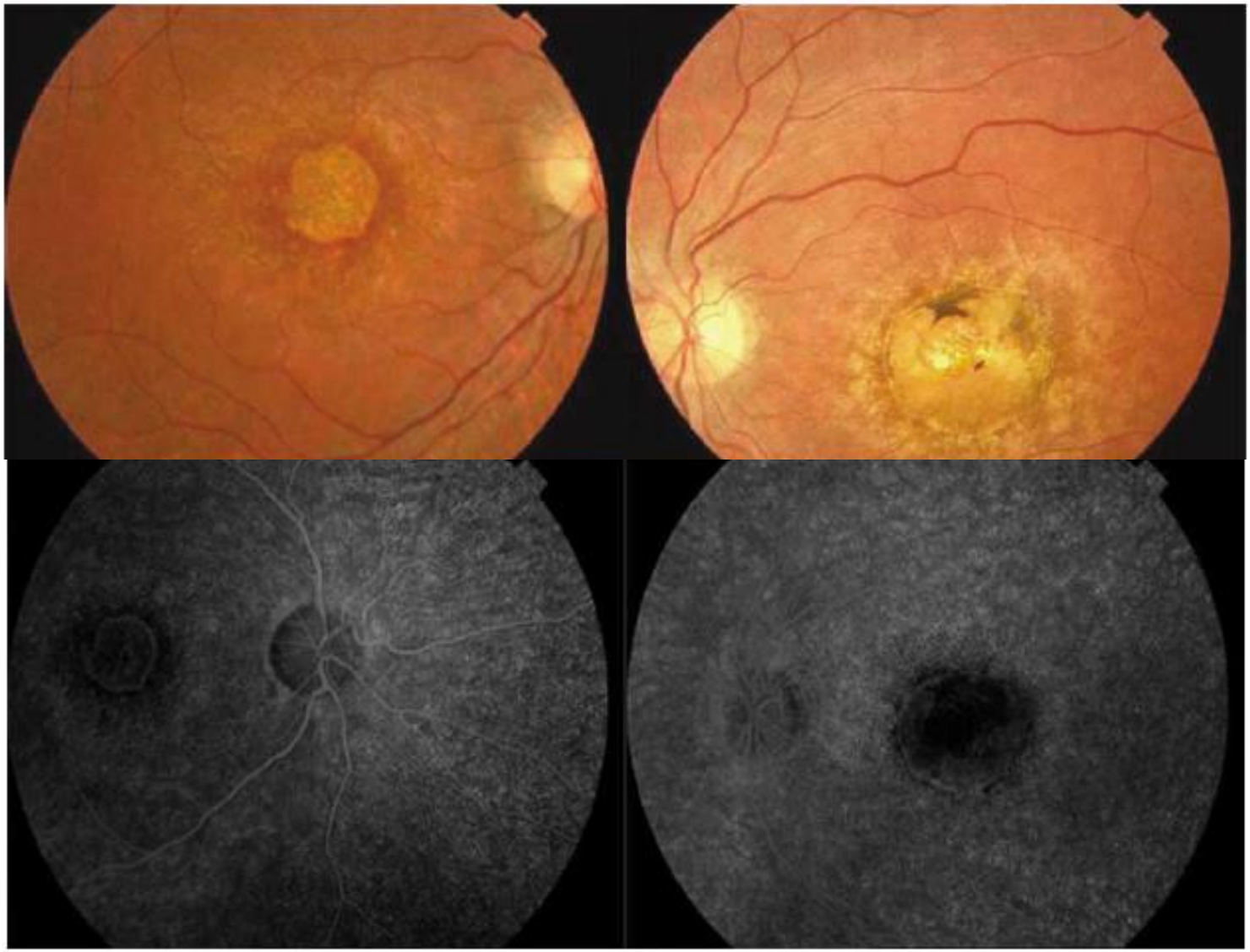

OCT: Sol göz

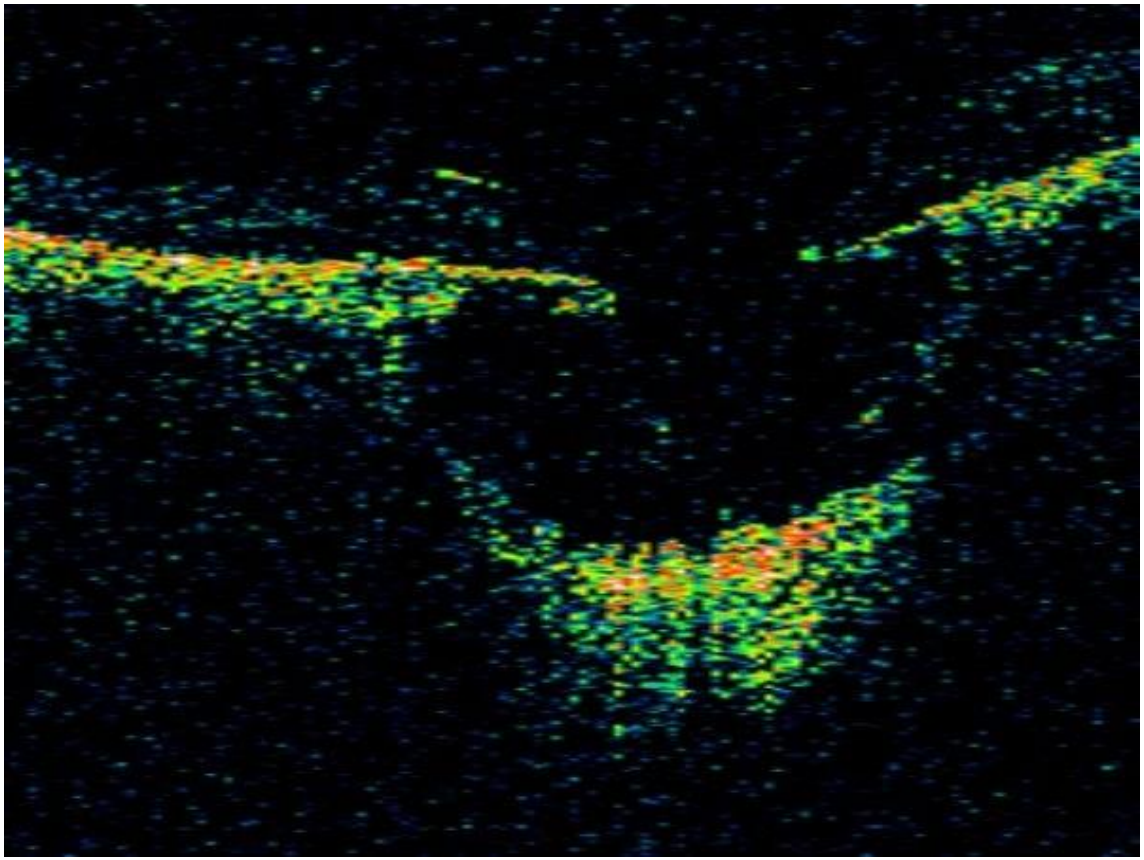

ERG: ciddi kon ve rod hasarı

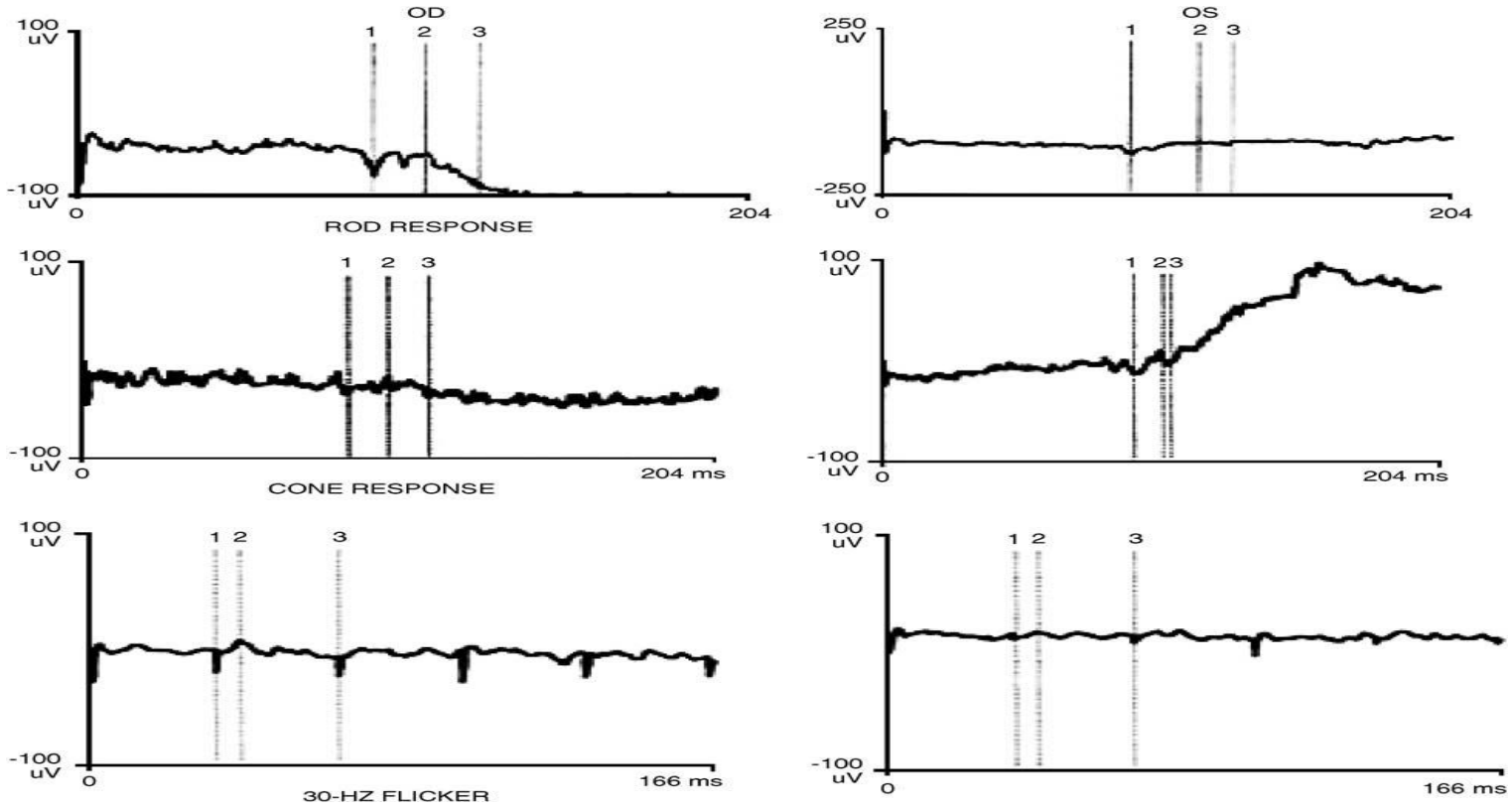

1. Erkek kardeş: 32y, GK: 0.6/0.7

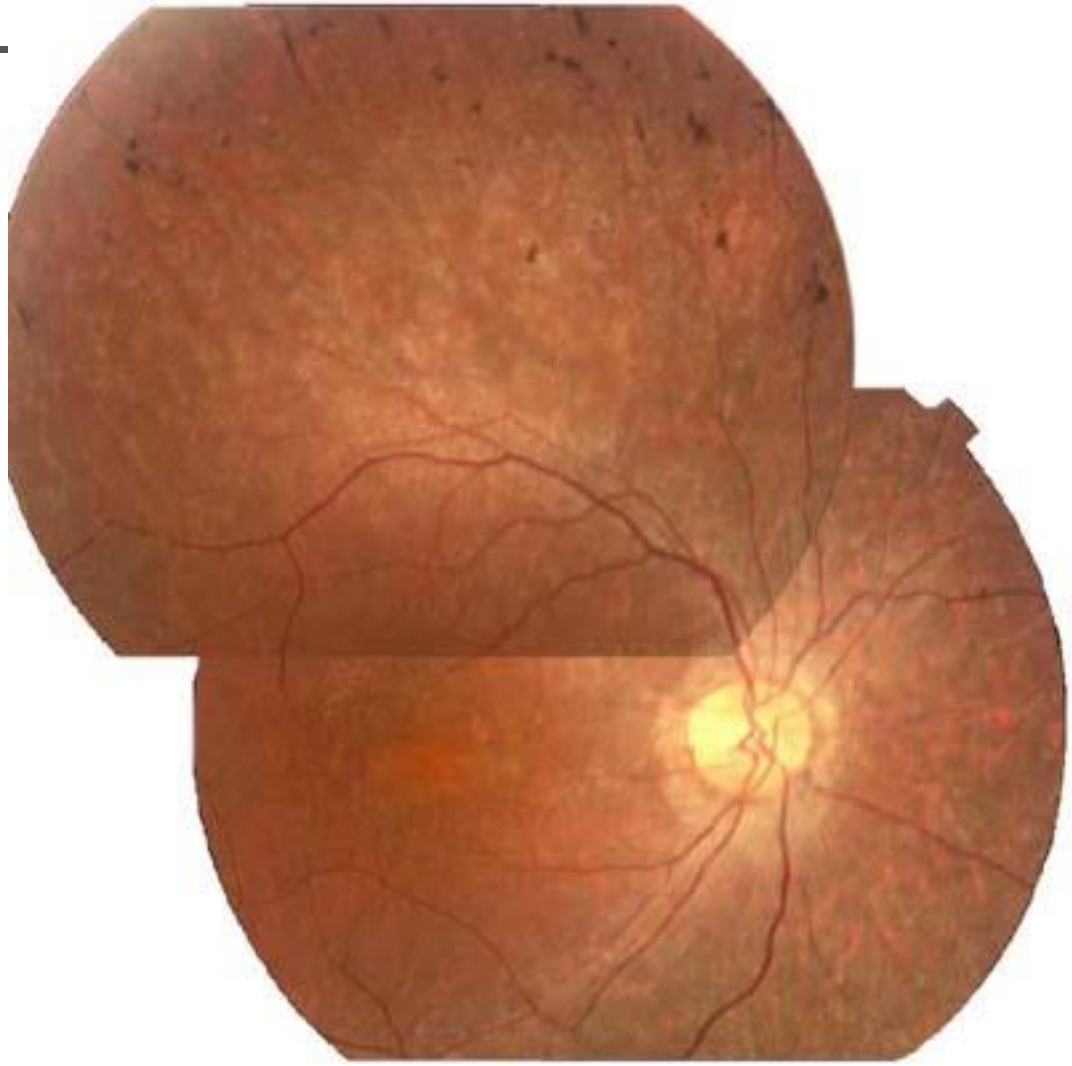

2. kardeş: 30 yaş, GK: 0.9/0.9
Tipik RP bulguları

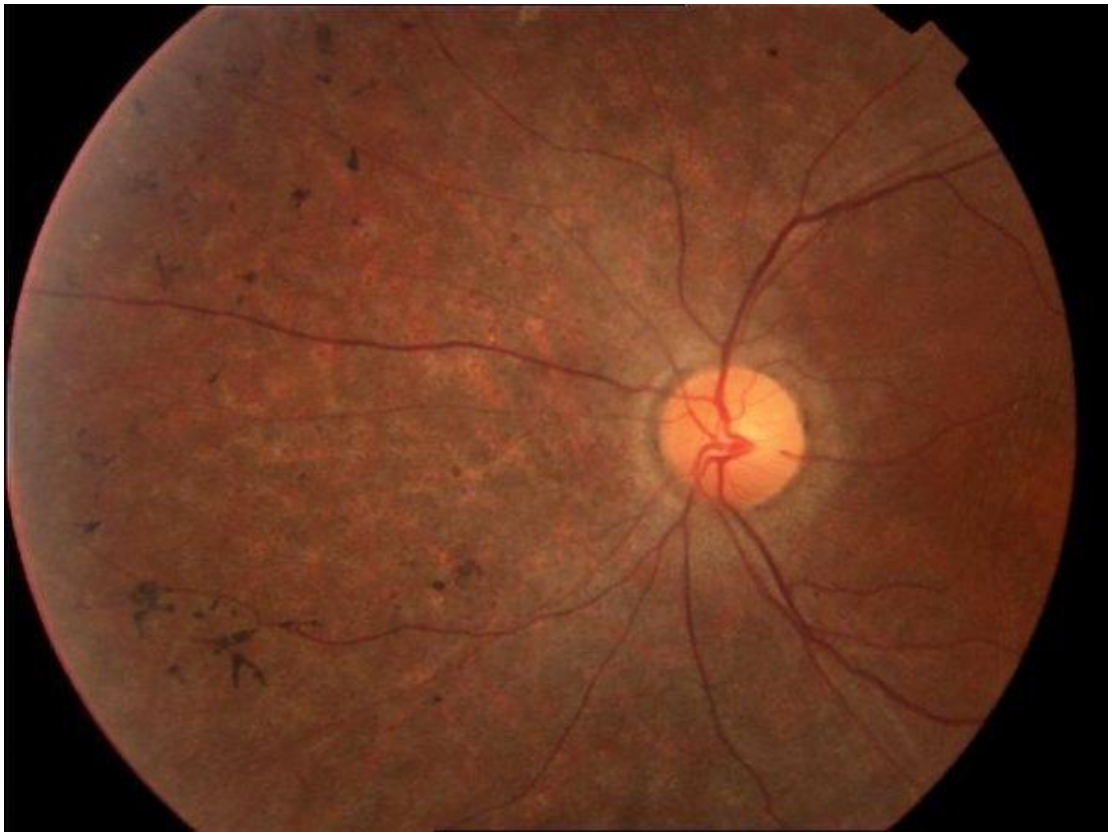

Genetik çalışma

- *ABCA4* geninde mutasyon (-)
- RDS periferin gen mutasyonu (-)

TEDAVİ

Tedavi

- ~~"Yapacak bir şey yok!"~~
- Katarakt cerrahisi, LVA
- KMÖ tedavisi: Asetazolamid
- Genetik danışmanlık
- Teknolojik gelişmelerden haberdar edilmesi
- Hastalığın gidişatının izlenmesi
  - Mesleki yönlendirme
  - Özürlülük hakları için rapor düzenleme

MUHTEMEL TEDAVİLER

- Vitamin A (15.000IU/gün) ???
- Antioksidan vitamin ve mineraller? DHA?
- Fazla ışıktan kaçınma?
- Ca kanal blokerleri?

- Hücre ve doku (kök hücre) transplant
- Silier nörotrofik faktör (CNTF)
- Retinal Protezler
- RPE65 gen tedavisi

Vit A

- 15.000IU/gün (Avicap, Avigen)
- RP hastalarında Cone ERG ve GA da progresyonu minimal azaltır!
- Hayvan çalışması desteklemiyor.
- Teratojenik
- Osteoporotik, KC toksisitesi

- Berson EL et al. 1993, Arch Ophthalmol.

Antioksidan vitamin ve mineraller?

- Vit E (400IU):
- Tek başına hastalığı hızlandırabilir….olumsuz etki!.. (kaçınılmalı)
- Vit A ile kombine ve düşük doz: faydalı?
- DHA: Yarar?

Işık maruziyeti (ADRP-sınıf B1)

- İlk raporlar anlamsız (Heterojen grup).
- Fakat ADRP'daki inf retinanın daha fazla etkilenmesi: Sup dan gelen ışık hasarı?
- Farklı mutasyonlara bağlı RP'lerde ışığın etkisi olabilir mi?
- Köpek modeli: RFF'ler FR dej arttırmış.
- Muayenelerde, RFF ve cerrahiler sırasında ışık maruziyetini azaltmalıyız!..
- Parlak güneş ışığından şapka ve güneş gözlükleri ile korunma önerilmeli.
- Uygun mutasyon gruplarında yeni ışık kısıtlama çalışmaları yapılmalı

YENİ TEDAVİLER

CNTF (Anti-apoptoz tedavi)

- Hayvan modelleri:
- Fotoreseptör dejenerasyonu geciktirir
- IV aylık enjeksiyonlar
- Yavaş salınım sistemleri
- Adeno ass-virus aracılı gen ted: Subret enjeksiyon
- BDNF: fotorec. Dış segmentlerinin yeniden oluşmasını sağlar.

RPE65
… is a candidate for gene therapy

Lancelot: 2001

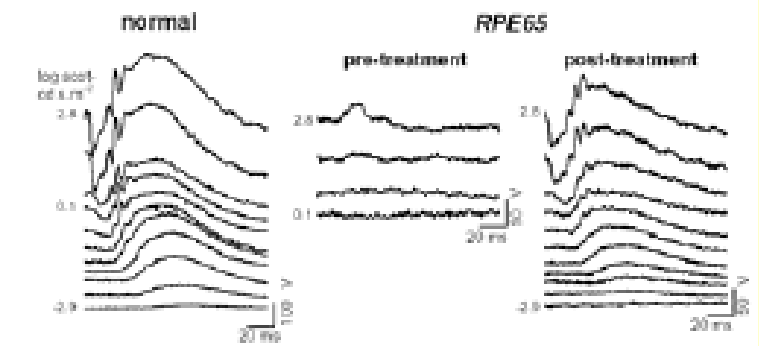

Acland G. M *et al*., 2001. Gene therapy restores vision in a canine model of childhood blindness. *Nat Genet* **28**, 92-95.

RPE-65 gen tedavisi (AAO-2009)

- RPE-65 AAV (Adeno associated virus) vektör aracılı gen transferi
- LCA
- CHOP-UPenn TIGEM SUN çalışması
  - 3/3 objektif ve subjektif iyilik
  - 12 hasta içeren çalışma başlatıldı.

MAKÜLA DİSTROFİLERİ

STARGARD HASTALIĞI (F. FLAVİMAKÜLATUS)

BEST HASTALIĞI

PATERN DİSTROFİLER, DOM. DRUSEN

NORTH CAROLINA M.DİSTROFİ

SORSBY MAKÜLER DİSTROFİ

“Flecked Retina”

- RPE’de veya altında sarımsı materyal birikimi
- Maküla ve retina-RPE hücreleri-koroidde progresif kayıp
- Erken hücre yaşlanması
- Kalıtsal genetik hastalık

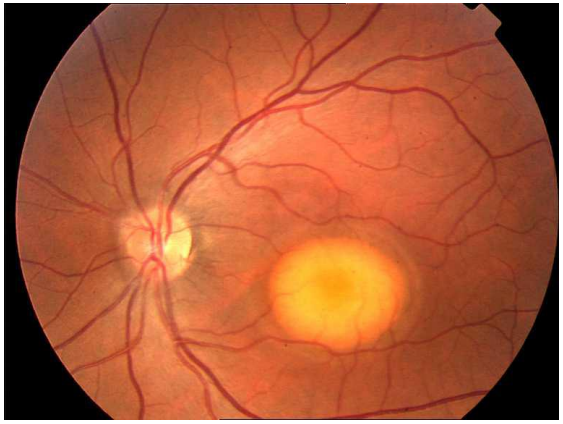

MAKÜLA VE RPE DİSTROFİLERİ

- Stargardt's Hastalığı (F. Flavimakülatus)
- Best Hastalığı
- Patern Distrofiler
- Dominant Drusen
- North Carolina M. Distrofi
- Sorsby Maküler Distrofi

Stargardt Hastalığı (F. Flavimakülatus)

- 1:8000–1:10000.
- En sık juvenil maküler dejenerasyon. (RD'lerin %7 si)
- Karl Stargardt (1909)
- Franceschetti: fundus flavimaculatus (1963)
- *ABCA4* geninde mutasyonlar (%60)

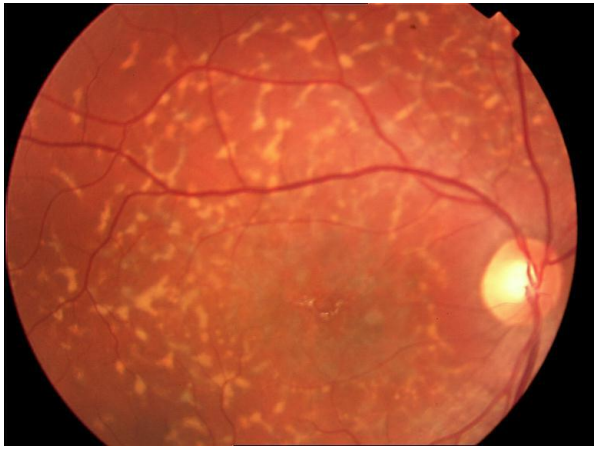

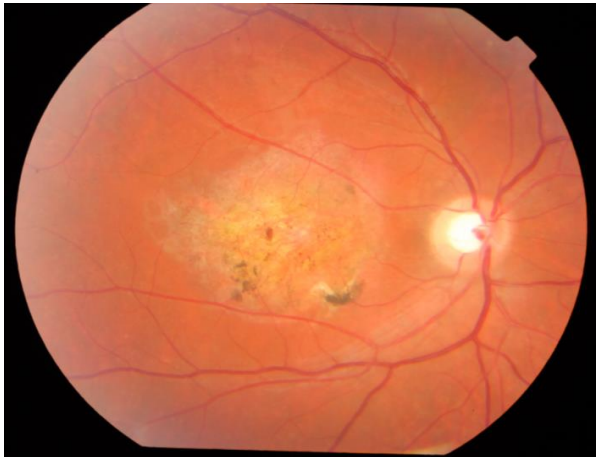

Stargardt Hastalığı (F. Flavimakülatus)

- Lipofuskinopati
- OR, OD (daha seyrek)
- 1. 2. dekad
- Santral görme kaybı,
- Bilateral atrofik fovea
- Subretinal flekler (sarı renkli)
- FFA: Dark koroid (sessiz koroid) (%80)

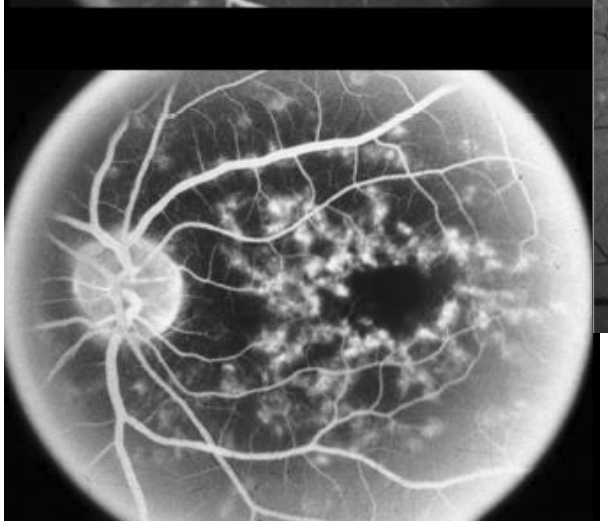

otofloesans

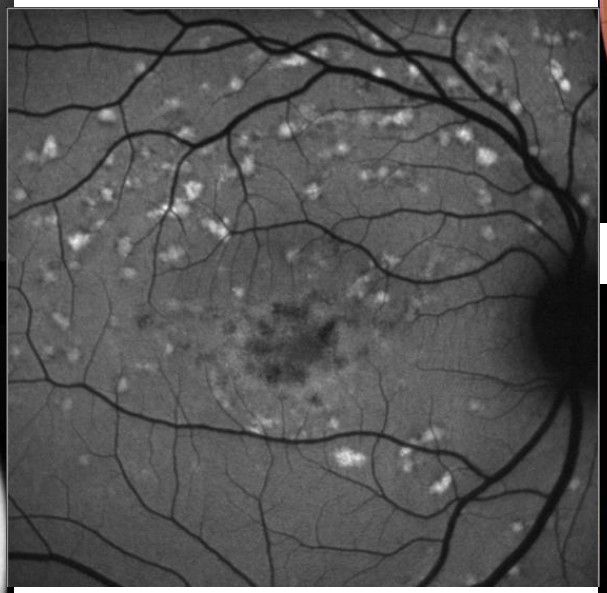

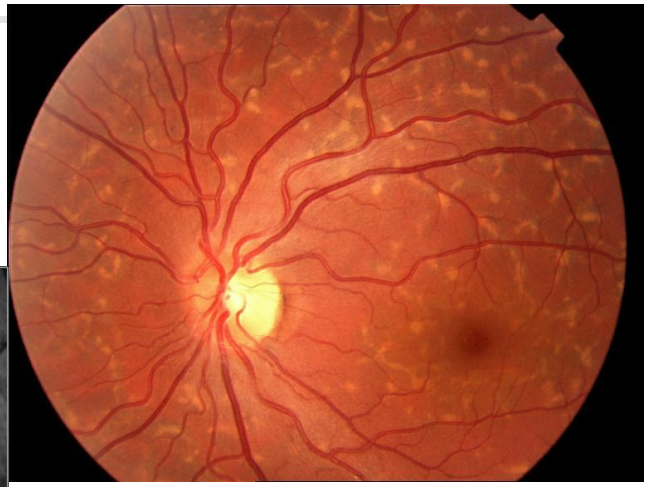

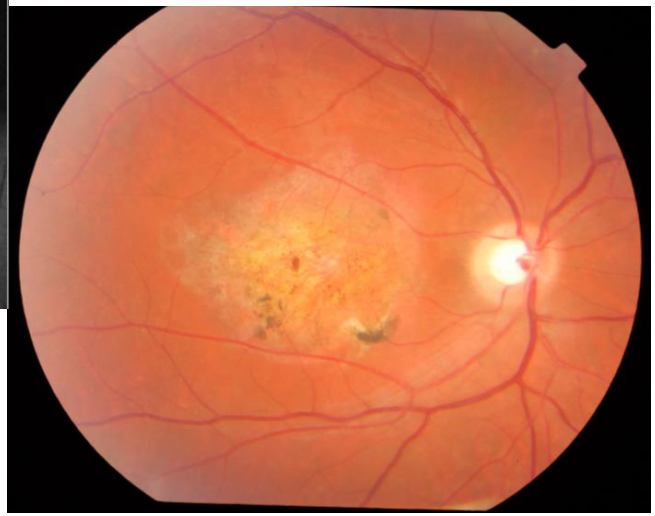

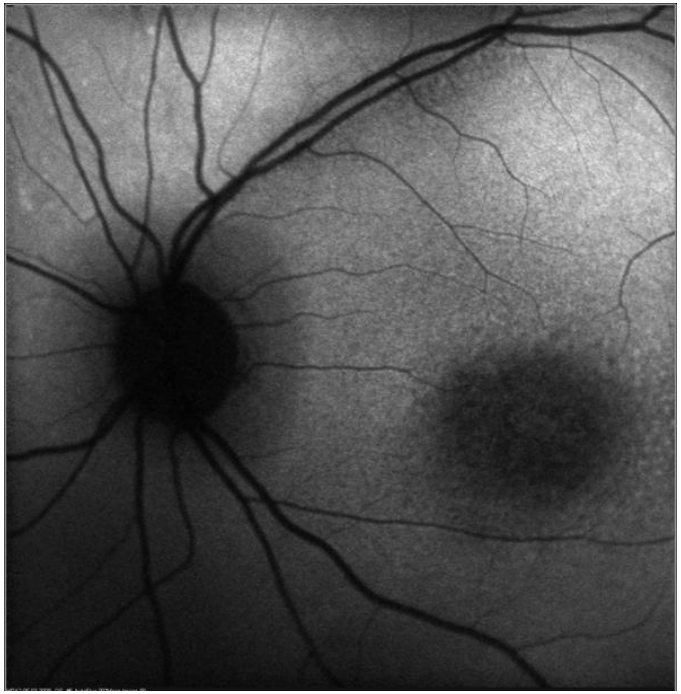

Dr. F. Batıoğlu'nun arşivinden

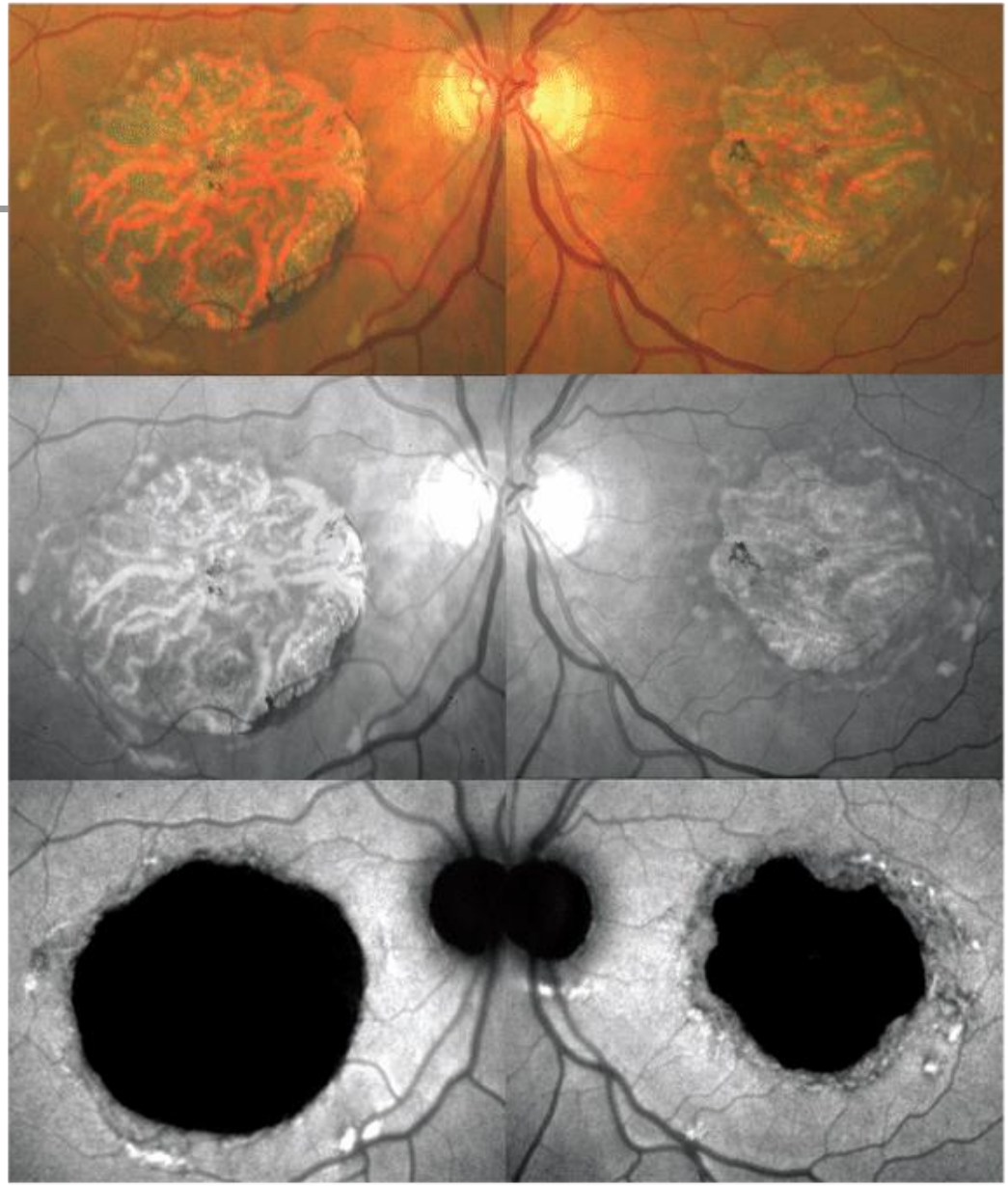

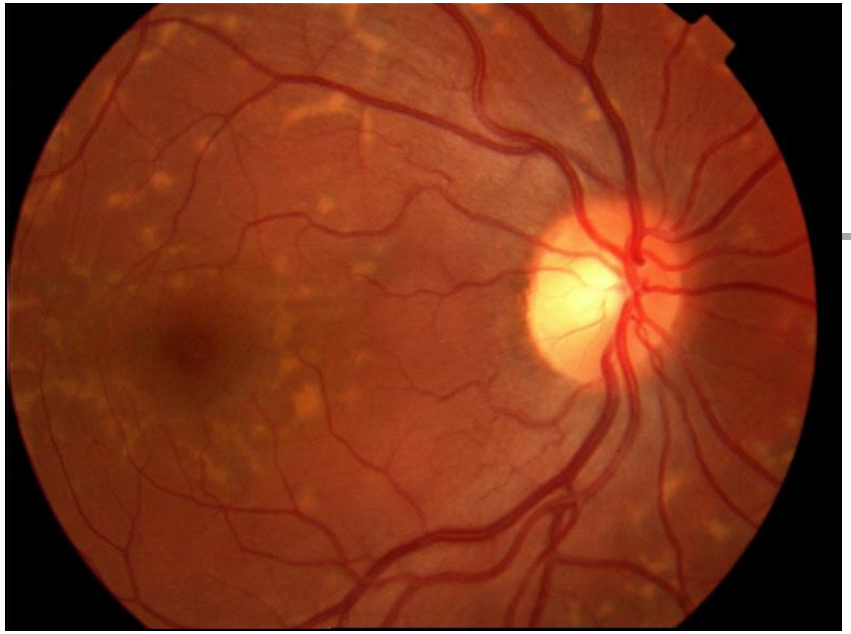

2001

2008

16y, E, Görme azlığı

- Anne baba 1. dereceden akrabalık
- 4 kız 1 erkek kardeş var: N
- Amca oğlunda görme azlığı (+)
- GK: K.M. Astig 0.15 / 0.15

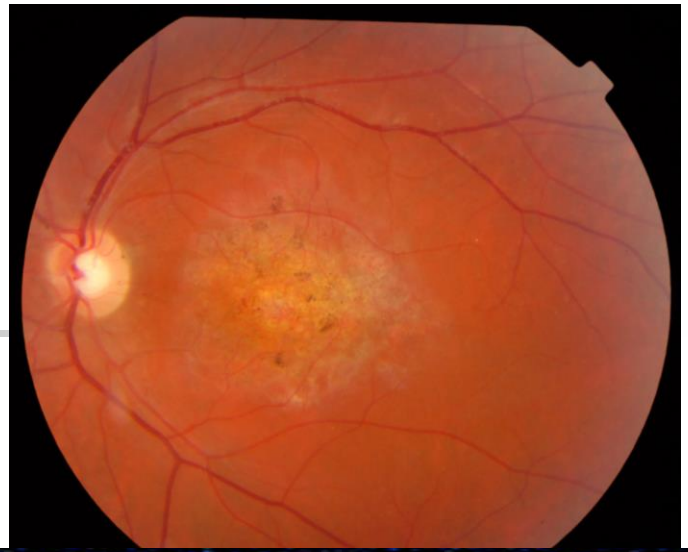

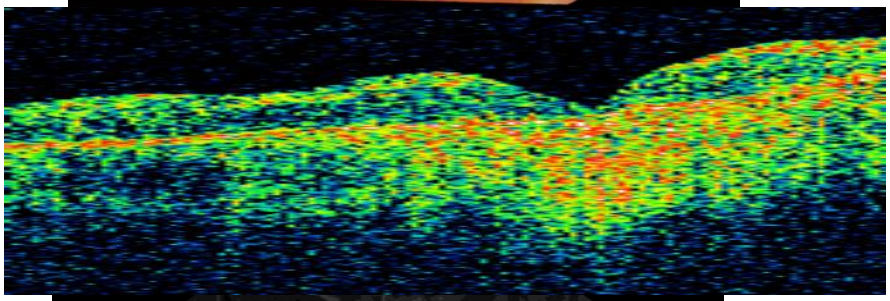

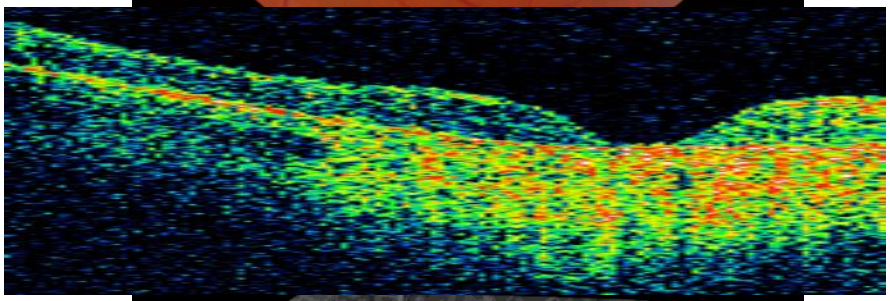

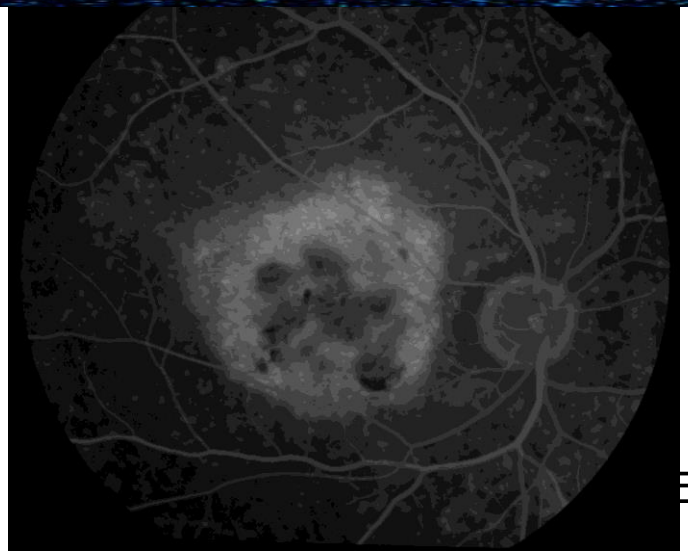

ERG: Subnormal

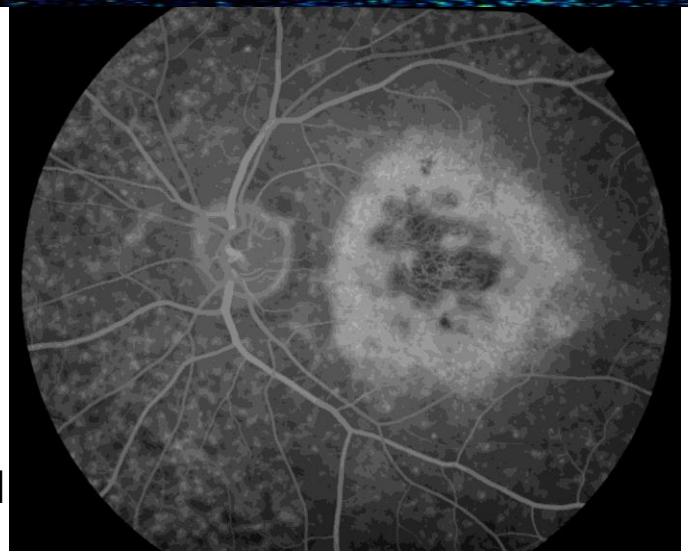

27y, E, Bilat görme azlığı
GK: 0.7/0.6

- Anne baba 2. derece akrabalık
- Kız kardeşte görme azlığı (+)
- 12 yıllık takip: GK: 0.1/0.05

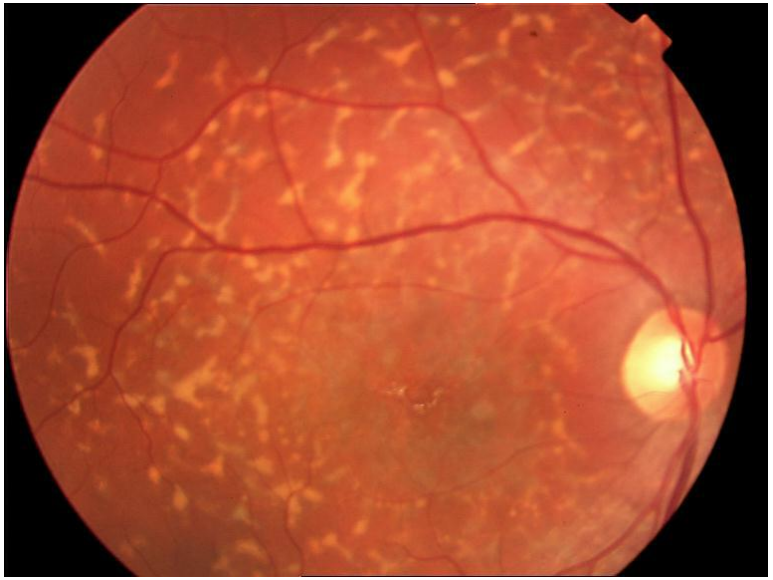

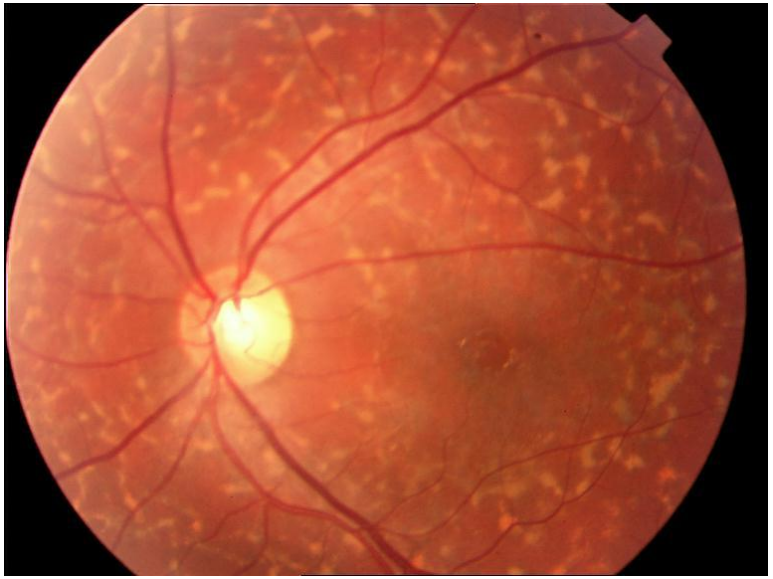

Kız kardeş: 25y, GK: 0.1/3mps

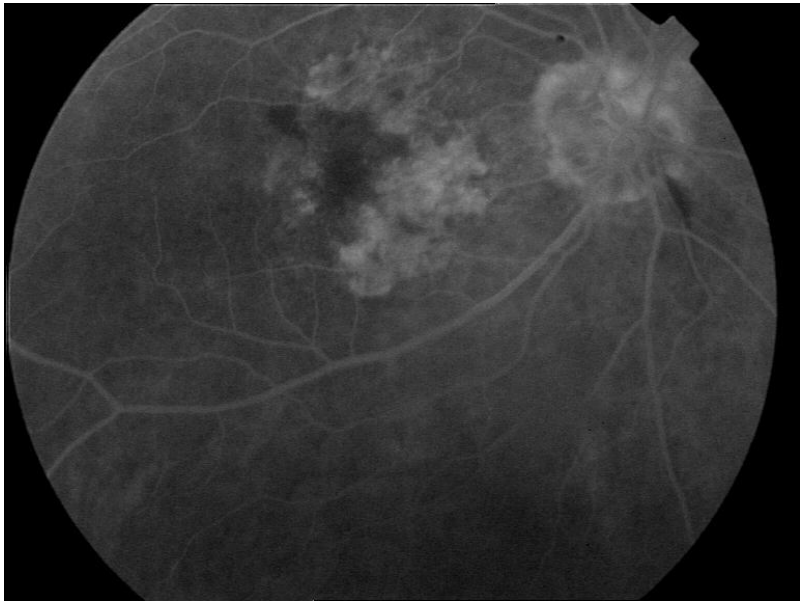

Tedavi

- İyi refraksiyon
- Az görenlere yardımcı cihazlar
- GK:0.1-0.2 olanlar normal okullara gidebilir.
- Danışmanlık:
  - Tam körlük (-)
  - Genellikle 0.1 civarında sabit görme
  - Genellikle OR, (çocukta hastalık riski %25)
  - Mesleki yönlendirme
  - Özürlülük hakları için rapor düzenleme

BEST HASTALIĞI

- Primer etkilenen: RPE
- Otozomal dominant

(%25 yeni sporadik mutasyon)

- Chr 11q13 (VMD2 geni)
- Tipik EOG bulgusu

Best – Tipik bulgular



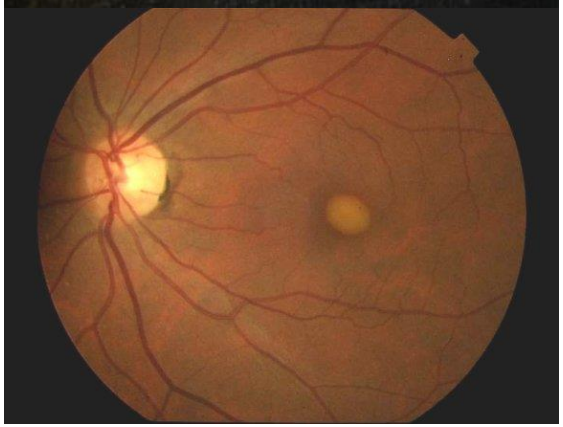

- Makulada tipik yumurta sarısı görünümü
- GK büyük lezyona oranla oldukça iyi!
- Anormal EOG: Arden oranı↓(<1.80)
- FFA'da bloke floresans
- OCT:

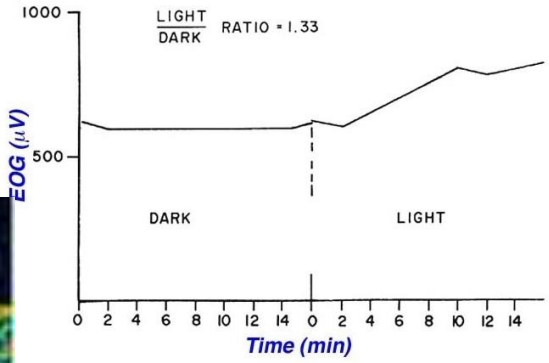

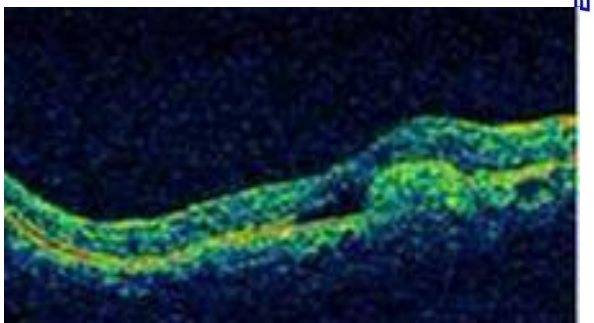

Semptomlar

- Erken evrede asemptomatik veya min GK↓
- İleri evrelerde orta düzeyde görme kaybı
- KNVM ile birlikte olabilir
- Subretinal hemoraji: minör travma ile

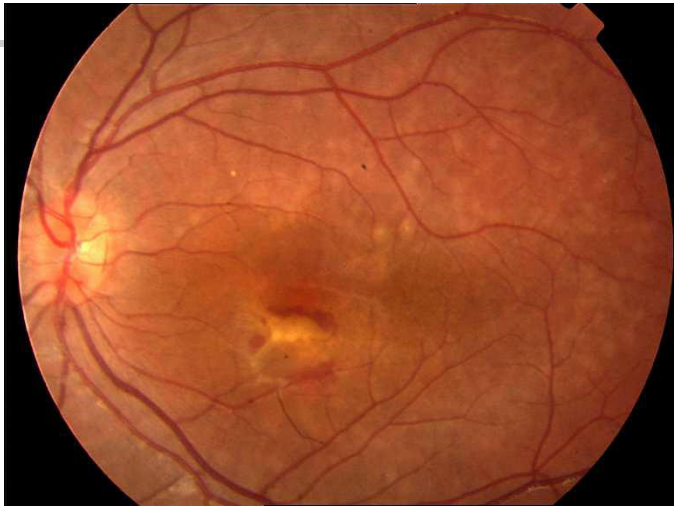

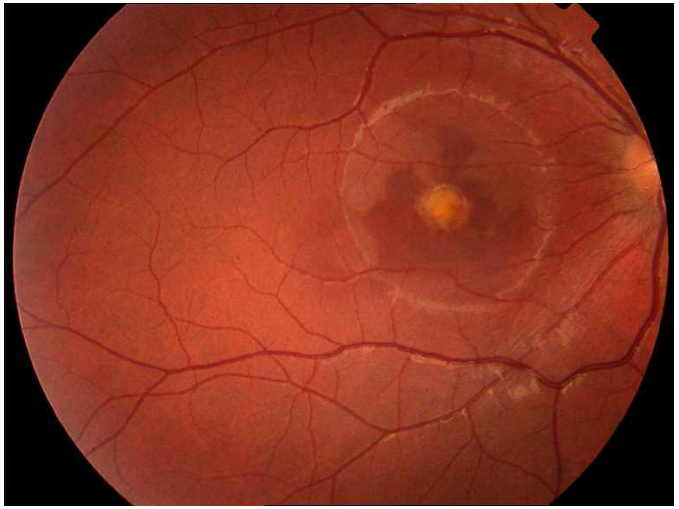

Evreler

- Previtelliform
- Vitelliform
- Psödohipopyon evre
- Vitellirüptif (Çırpılmış yumurta) evresi
- Atrofik, Skatrisyel evre (KNV)

Vitelliform Evre

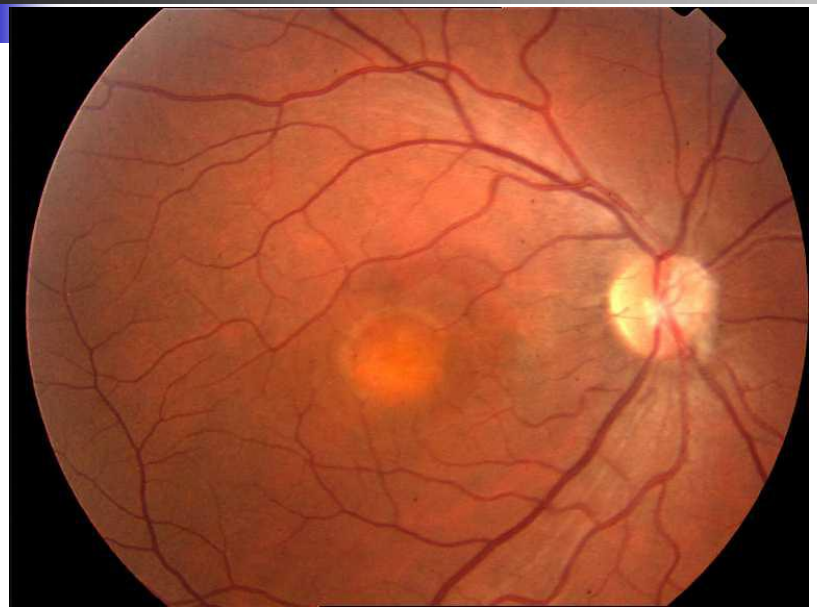

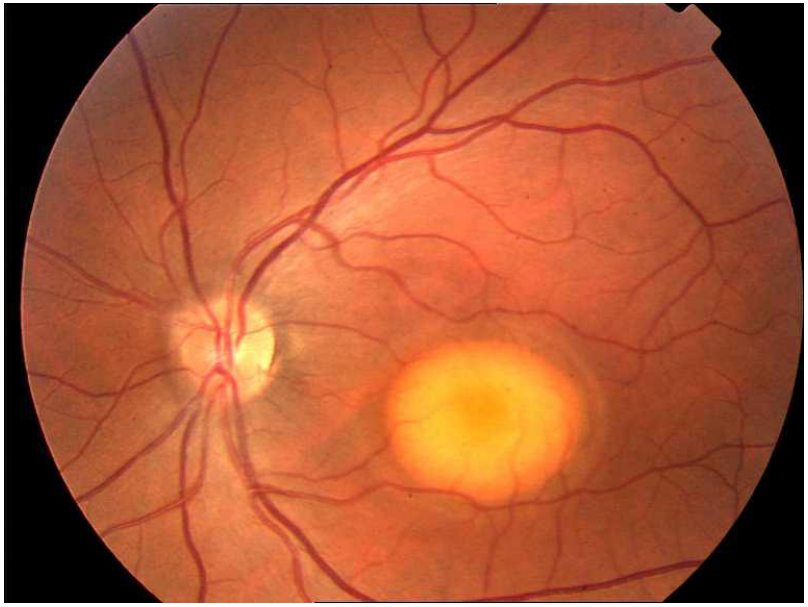

- 34y, KG, E, bulanık görme,
- Ailede toplam 9 kişide (anne, dede, dayı, kuzenler, 1 kardeşte) benzer sorun

GK: 1.0/1.0, EOG: Arden: 1.48 (Temmuz 2004)

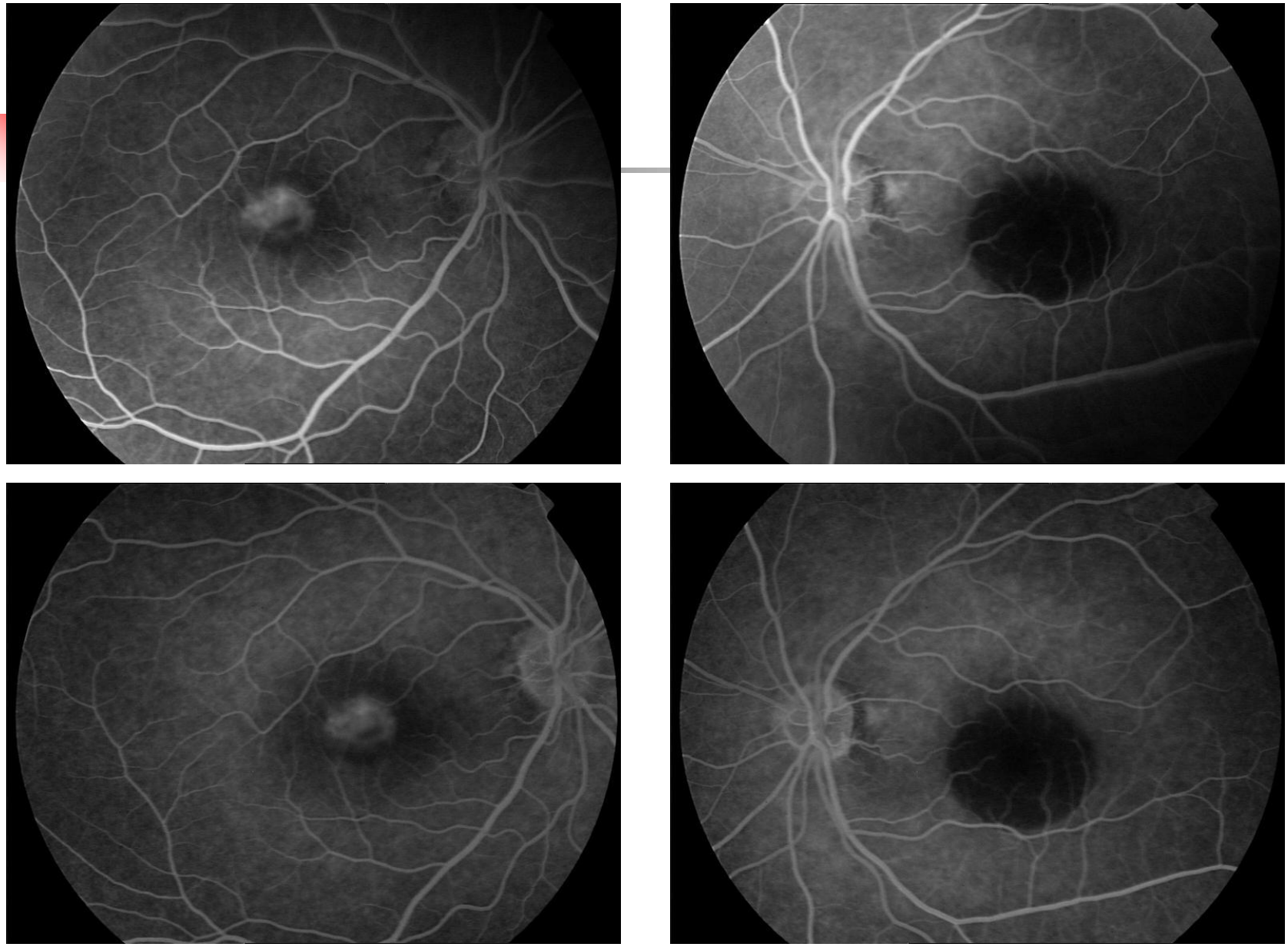

GK: 0.9/0.9, (2006-2 yıl sonra)

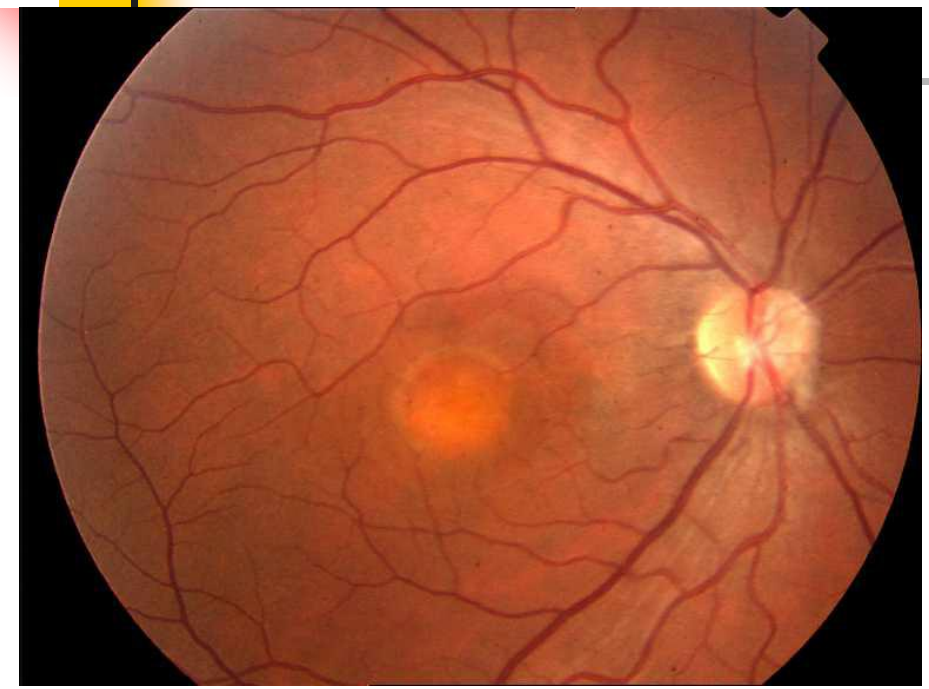

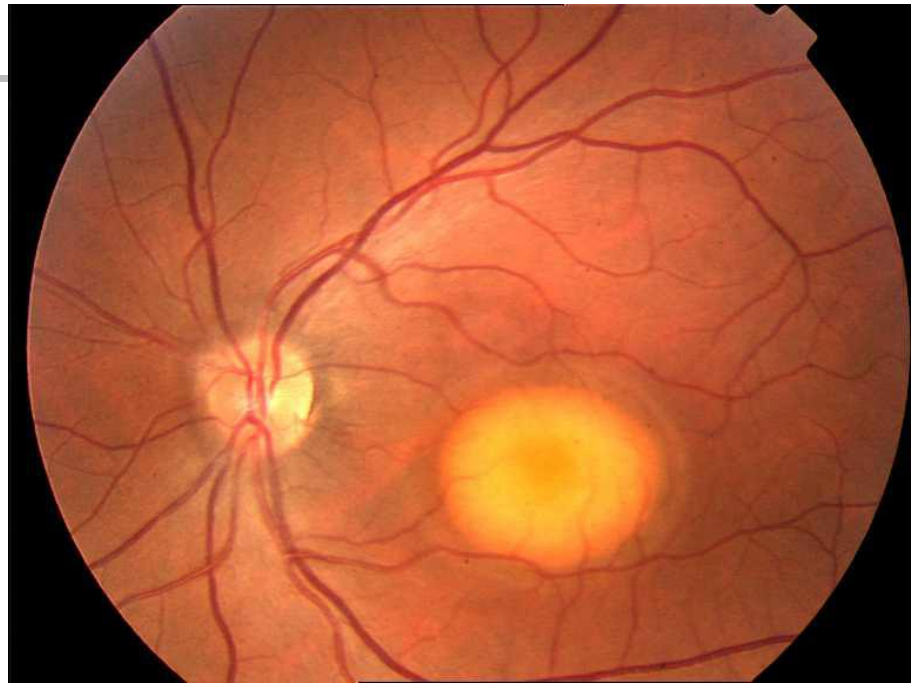

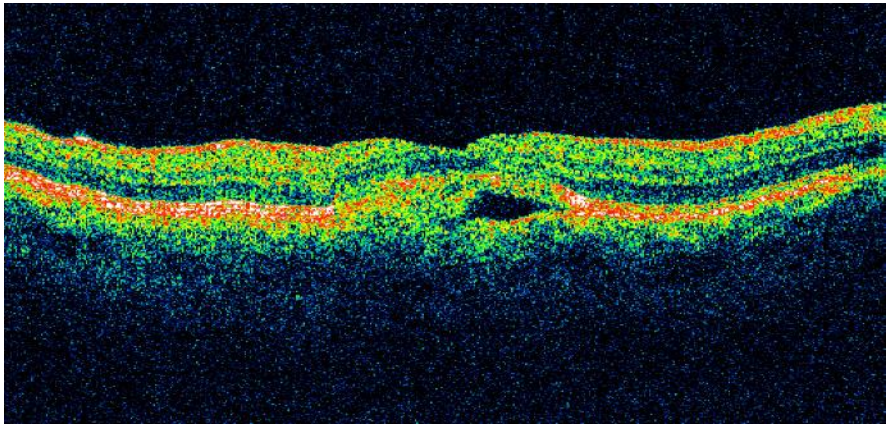

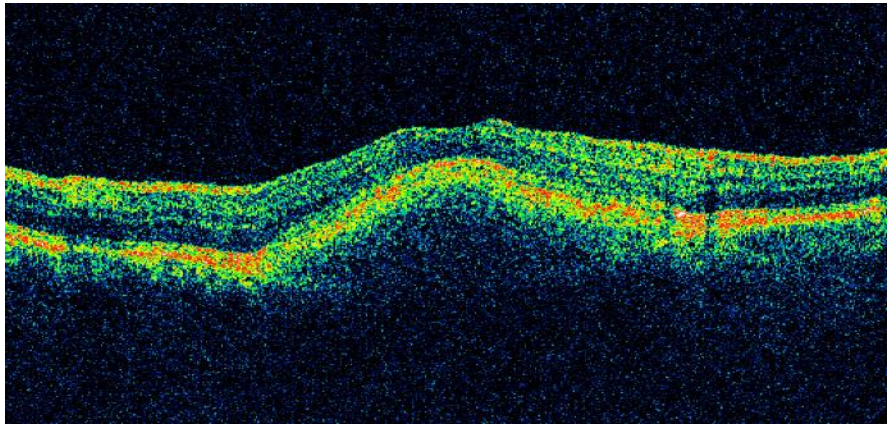

Psödohipopyon evresi

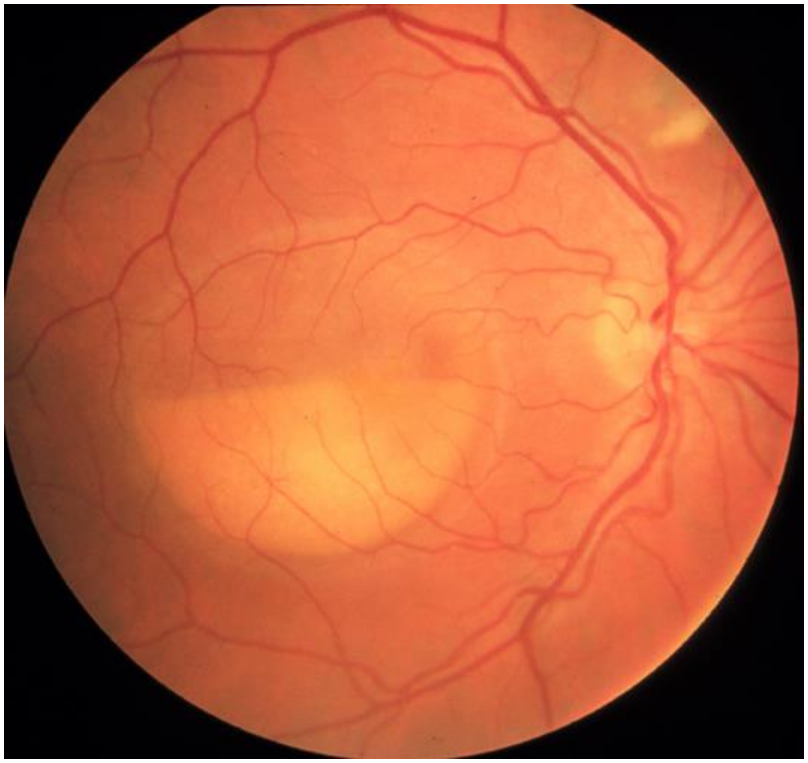

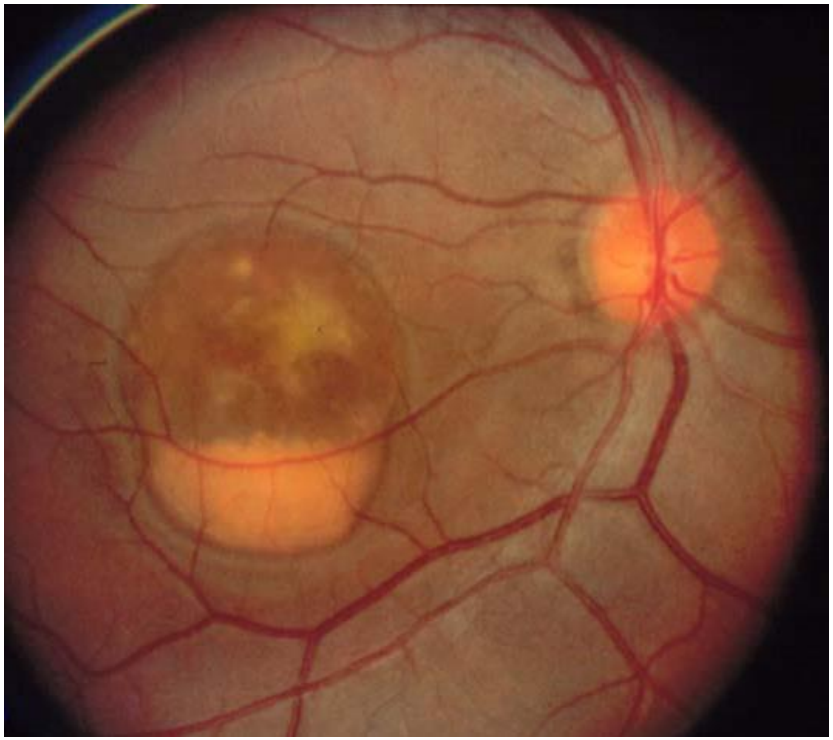

OCT

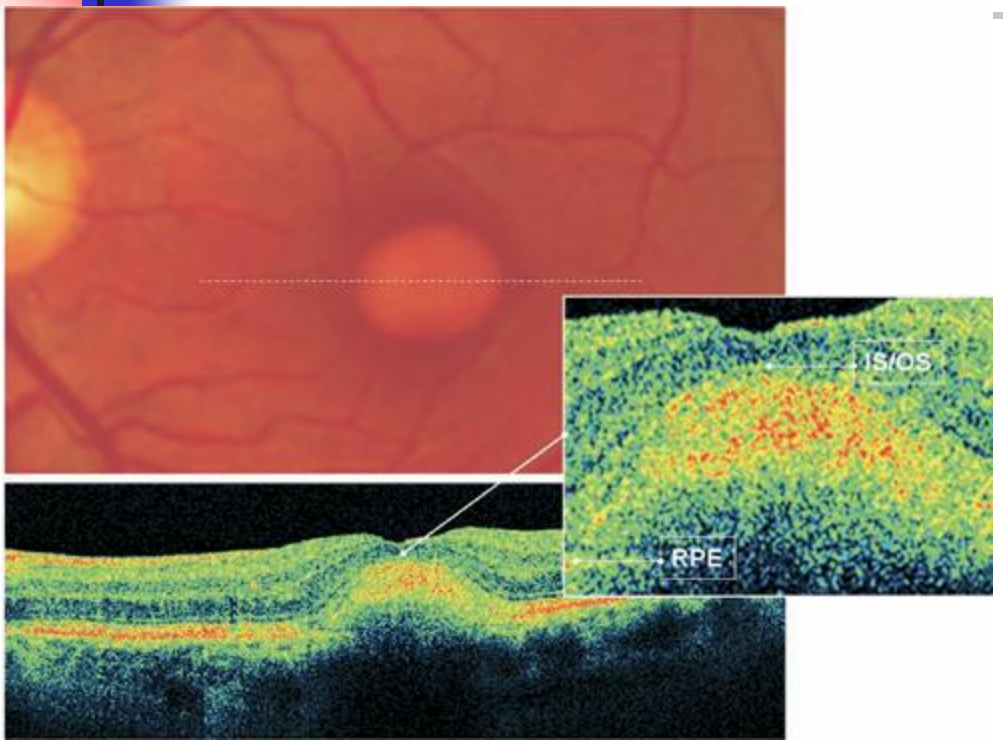

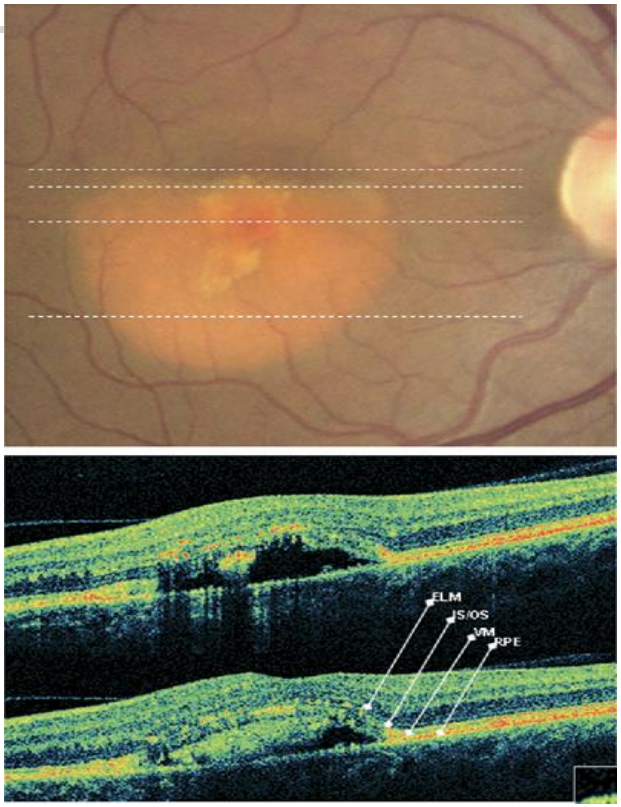

Vitellirüptif
Çırpılmış yumurta evresi

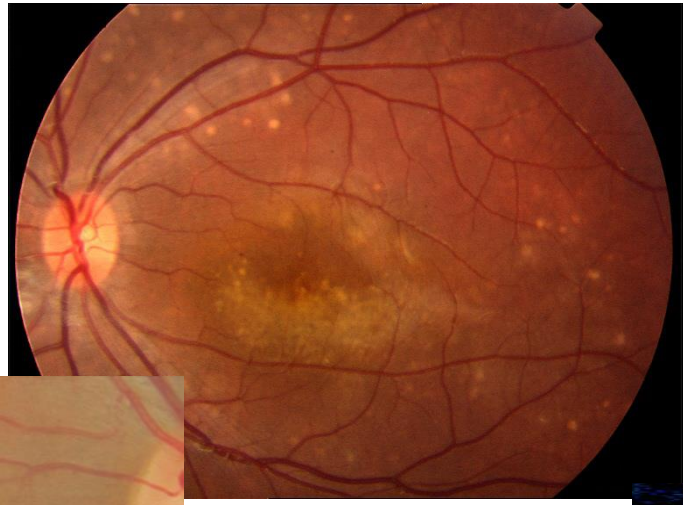

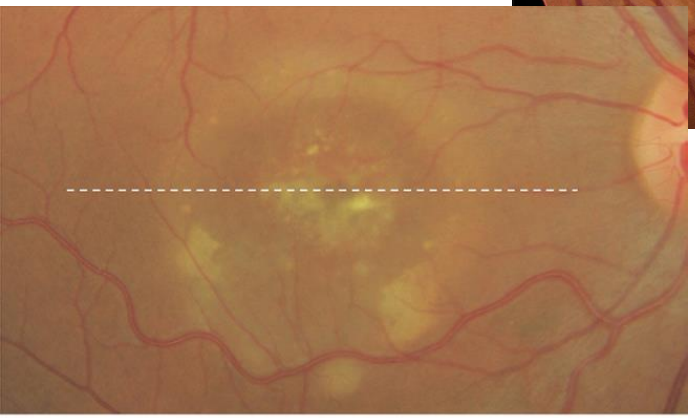

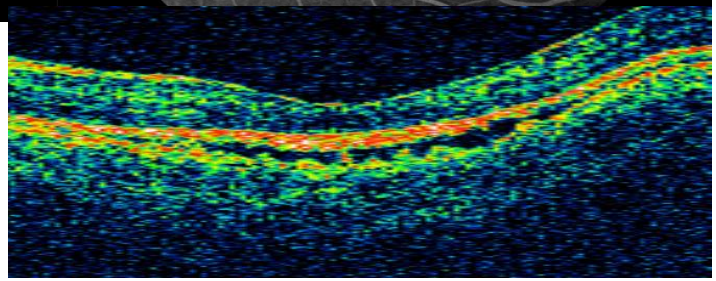

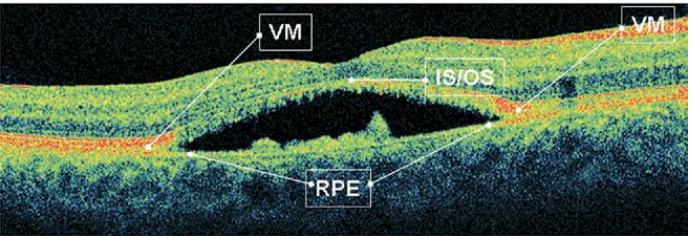

Atrofik - Skatrisyel evre

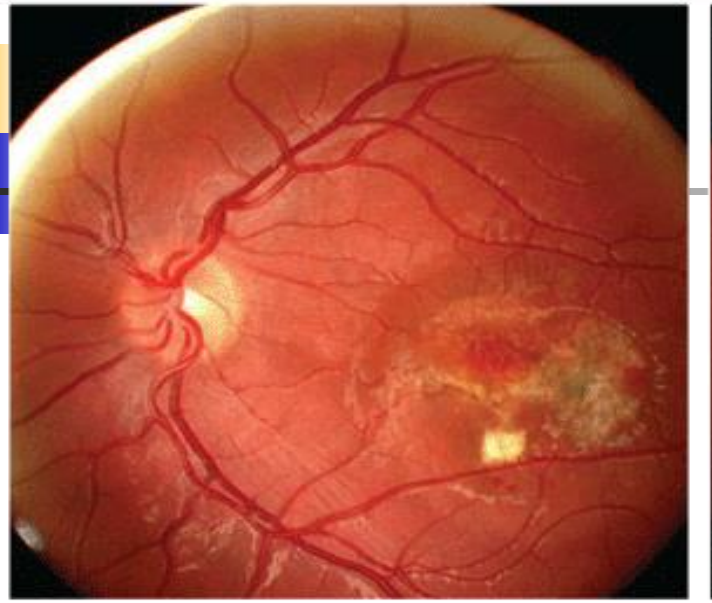

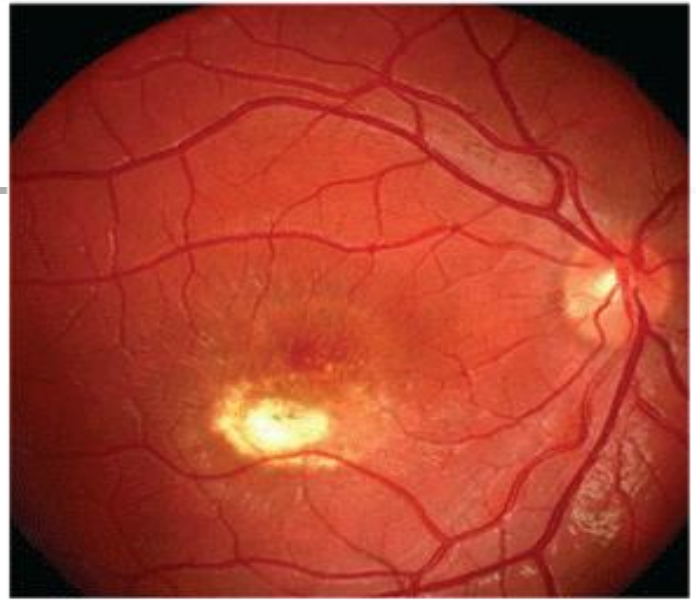

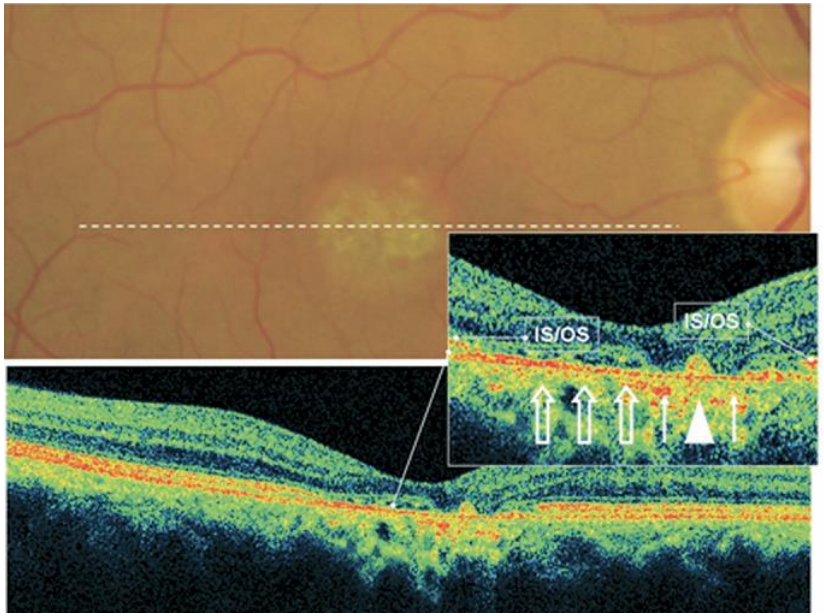

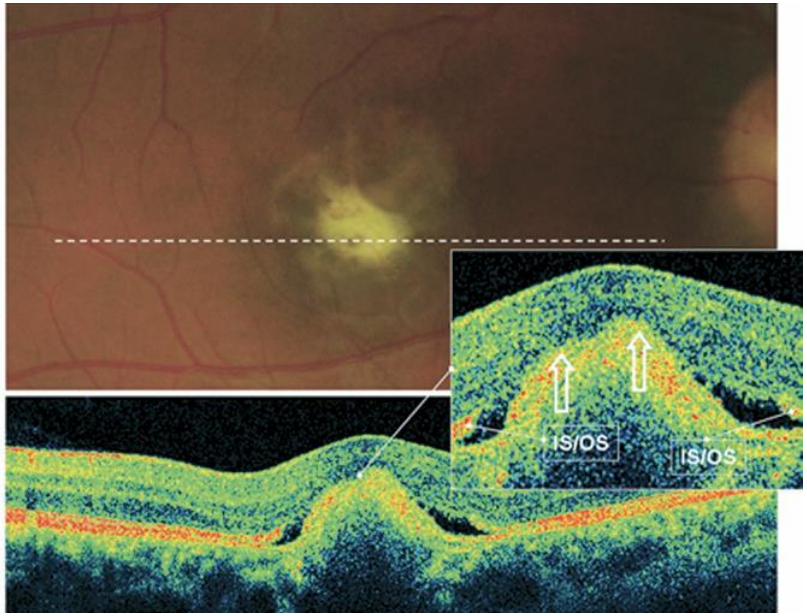

Otofloresans

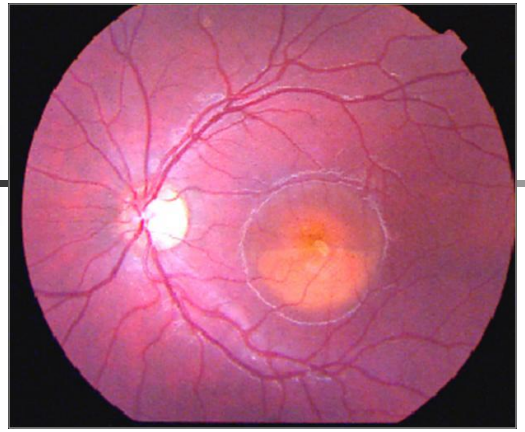

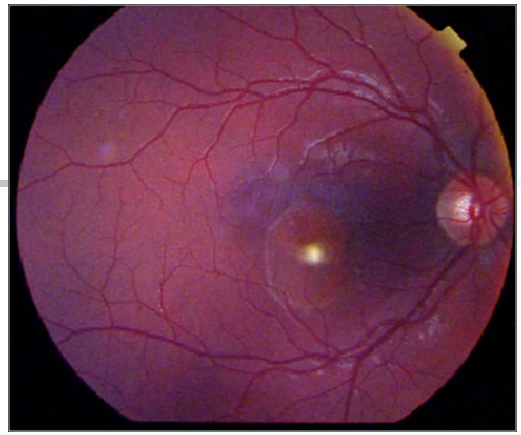

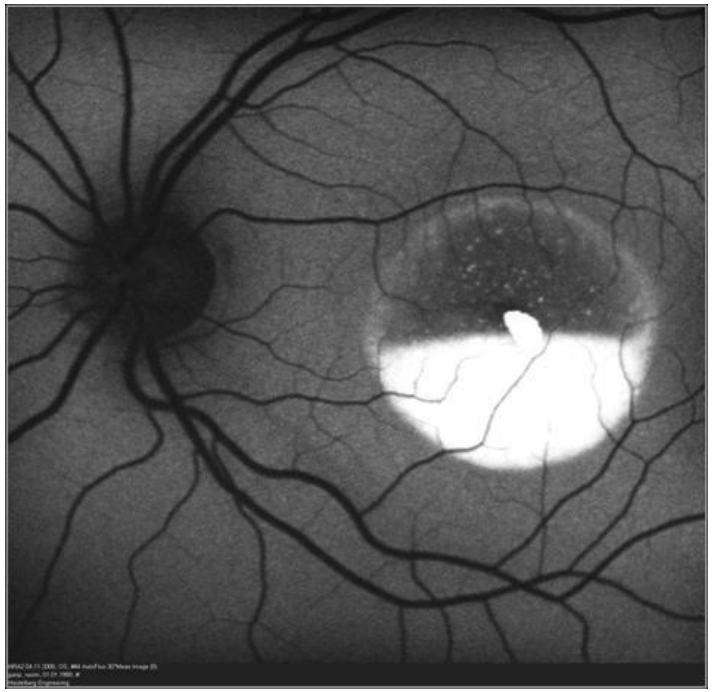

Dr. F. Batıoğlu'nun arşivinden

8yaş kız, GK: 0.05, 0.6
aile hik: anne, erkek kardeş, dayı ve dede de görme azlığı,
EOG: Arden oranı: 1.32

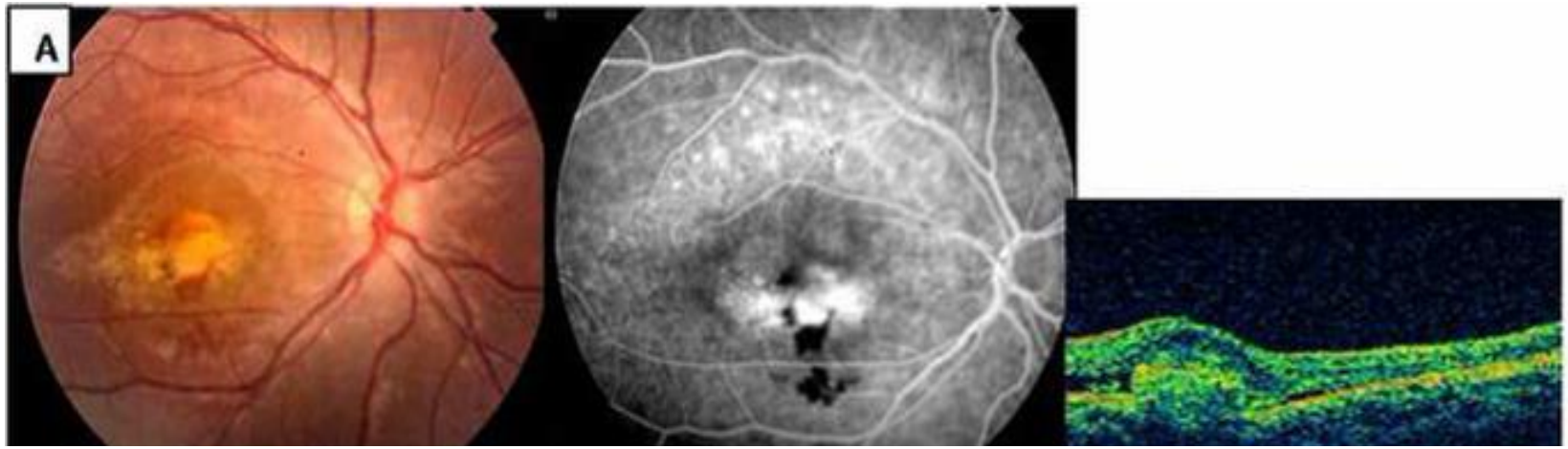

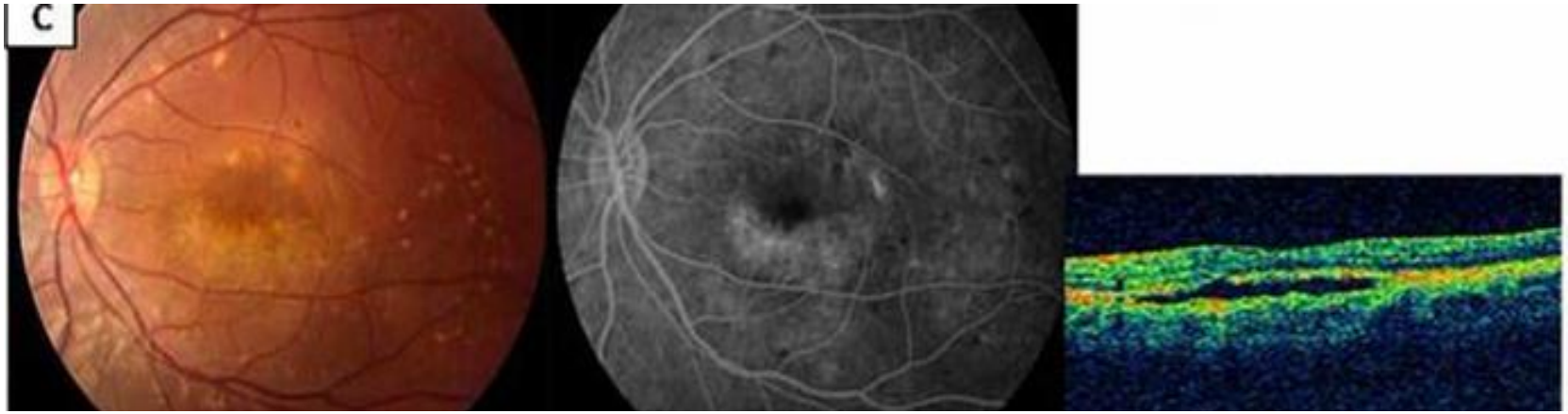

PDT: 1x, 26 aylık takip, GK: 0.2 (2. ay-26.ay)

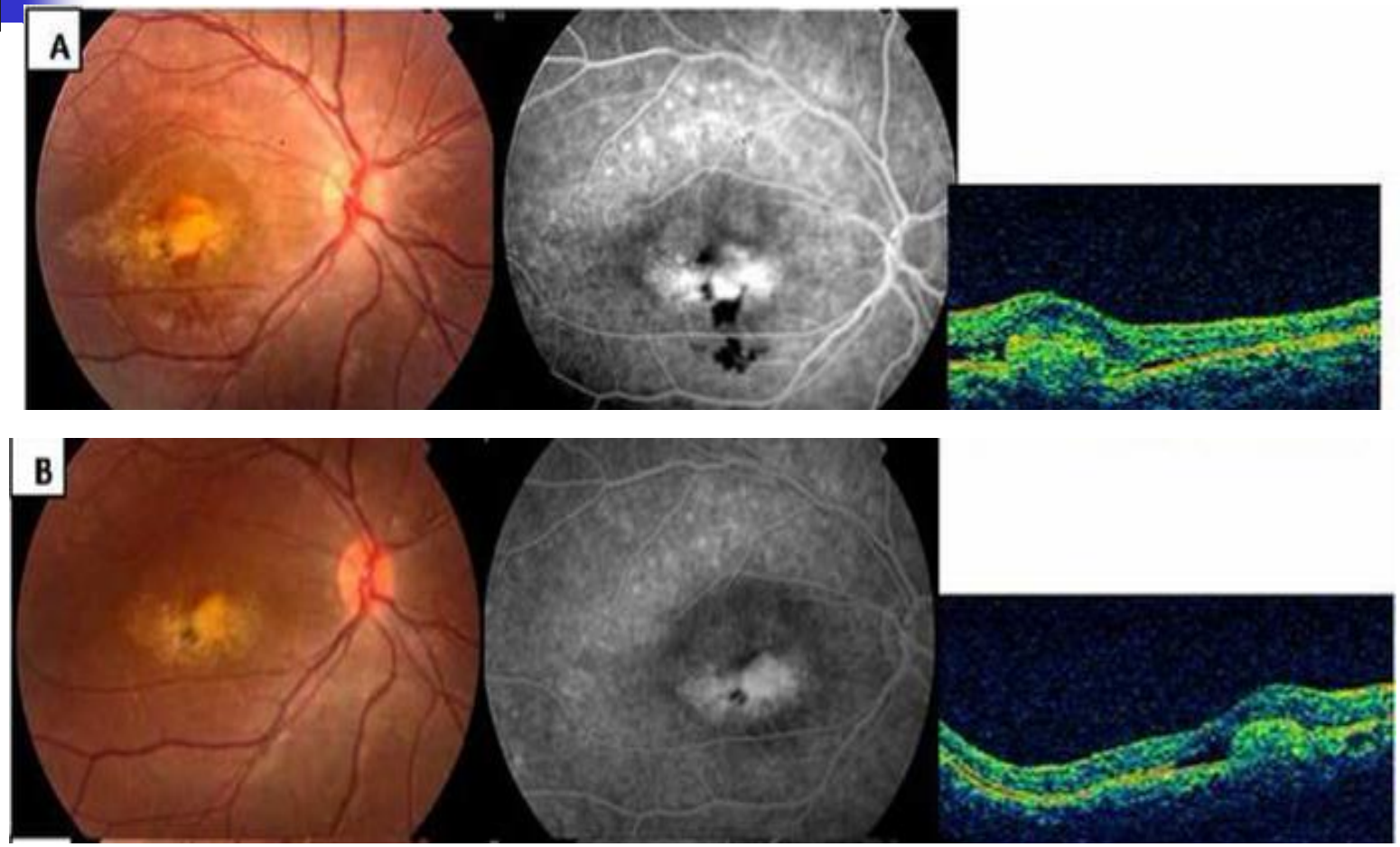

12y, E, aile hik (-), GK: 0.3/ Tam, EOG: 1.2/1.1

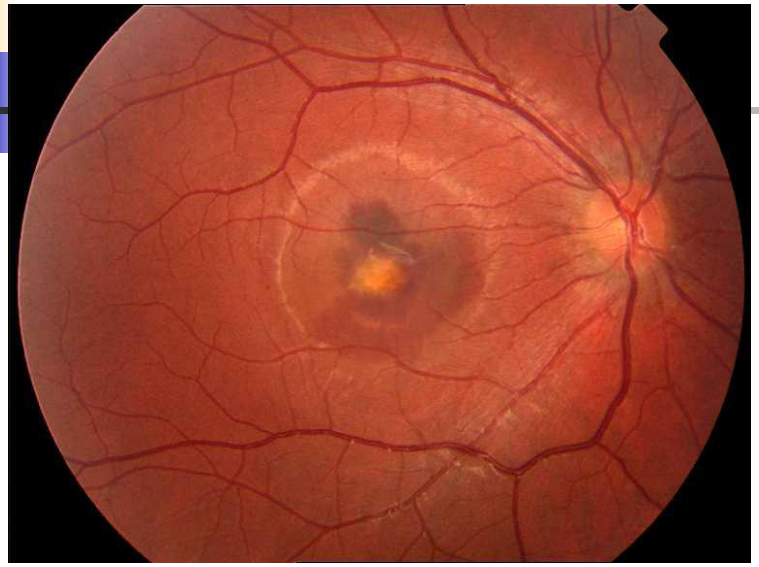

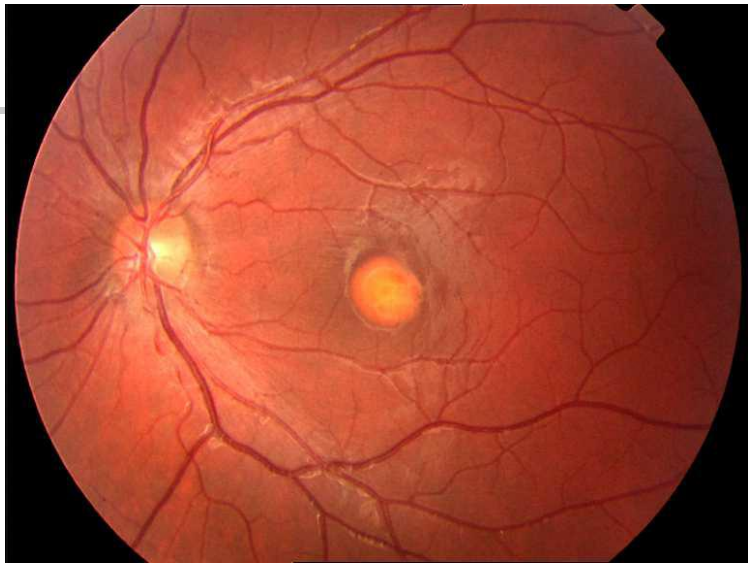

Sağ: PDT, (2.ay-23 ay sonra), GK: 0.9/Tam

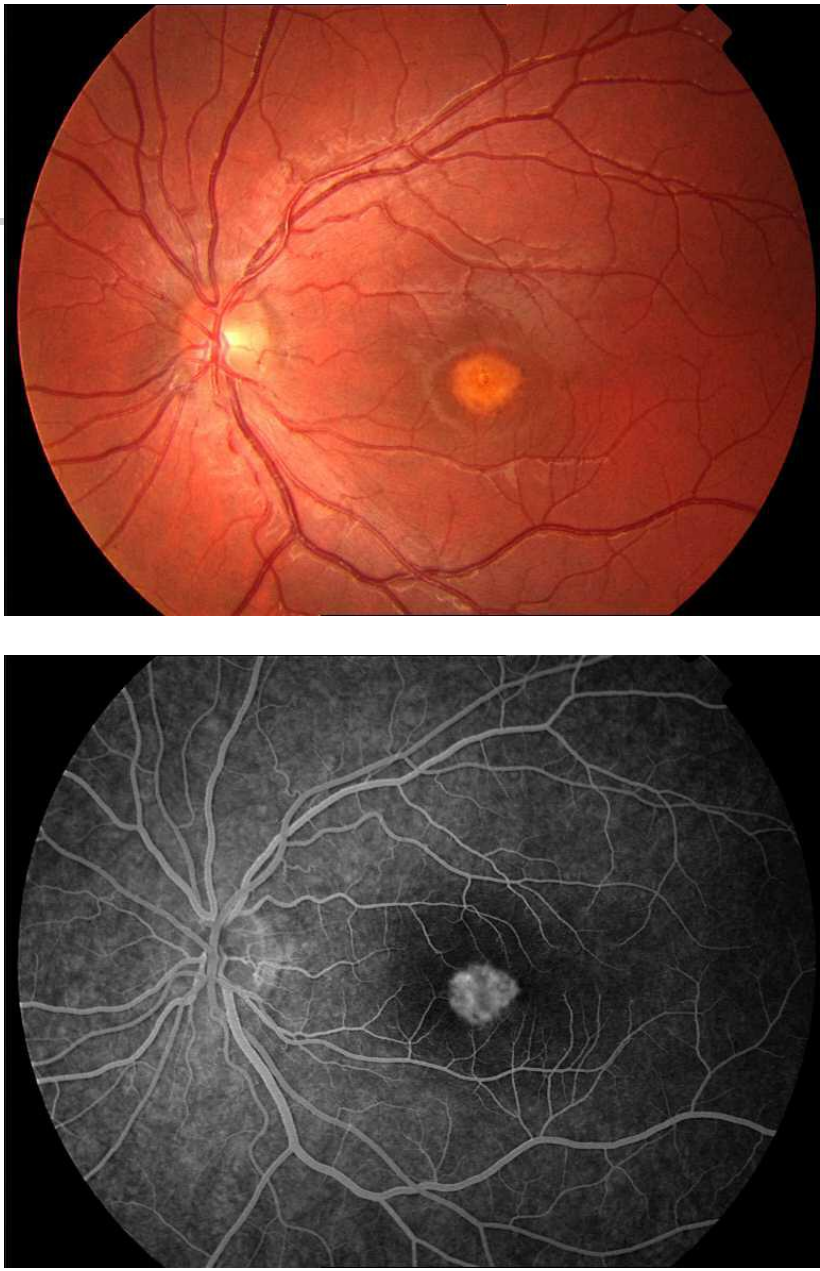

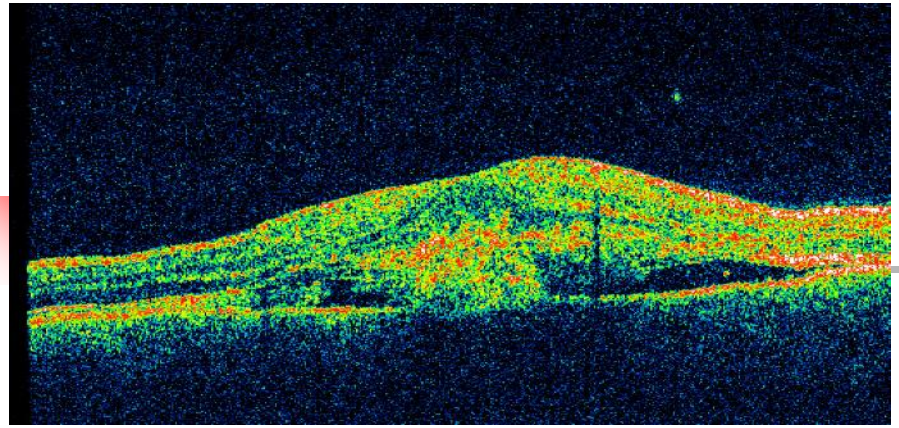

Post PDT 2.ay

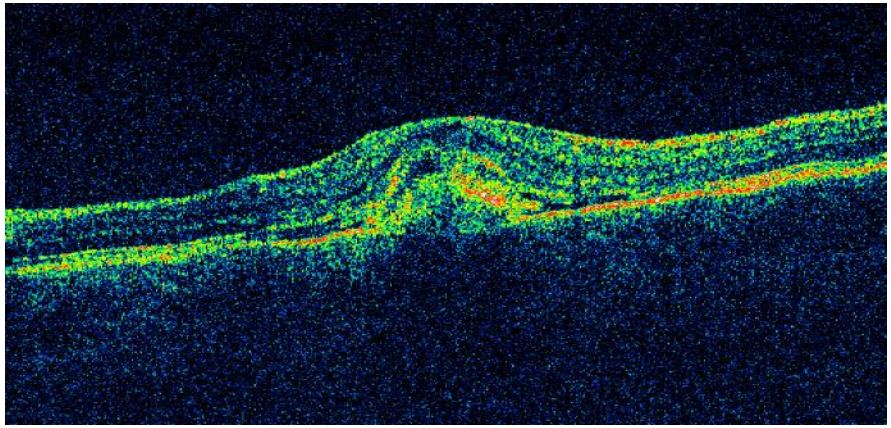

Post PDT 23.ay

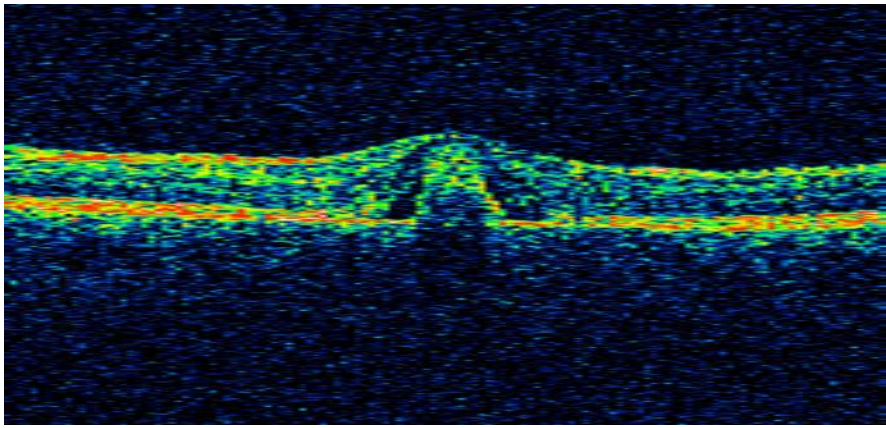

Danışmanlık

- Görme kaybı yavaş ve >40 yaş
- Genellikle bir gözde hayat boyu okumaya yeterli görme
- Mesleki yönlendirme!...

Patern Distrofi

Özdek Ş, ve ark. Retina pigment epitelinin patern distrofisi ve koroidal neovaskülerizasyon. Ret-Vit, 2006: 14:11-16.

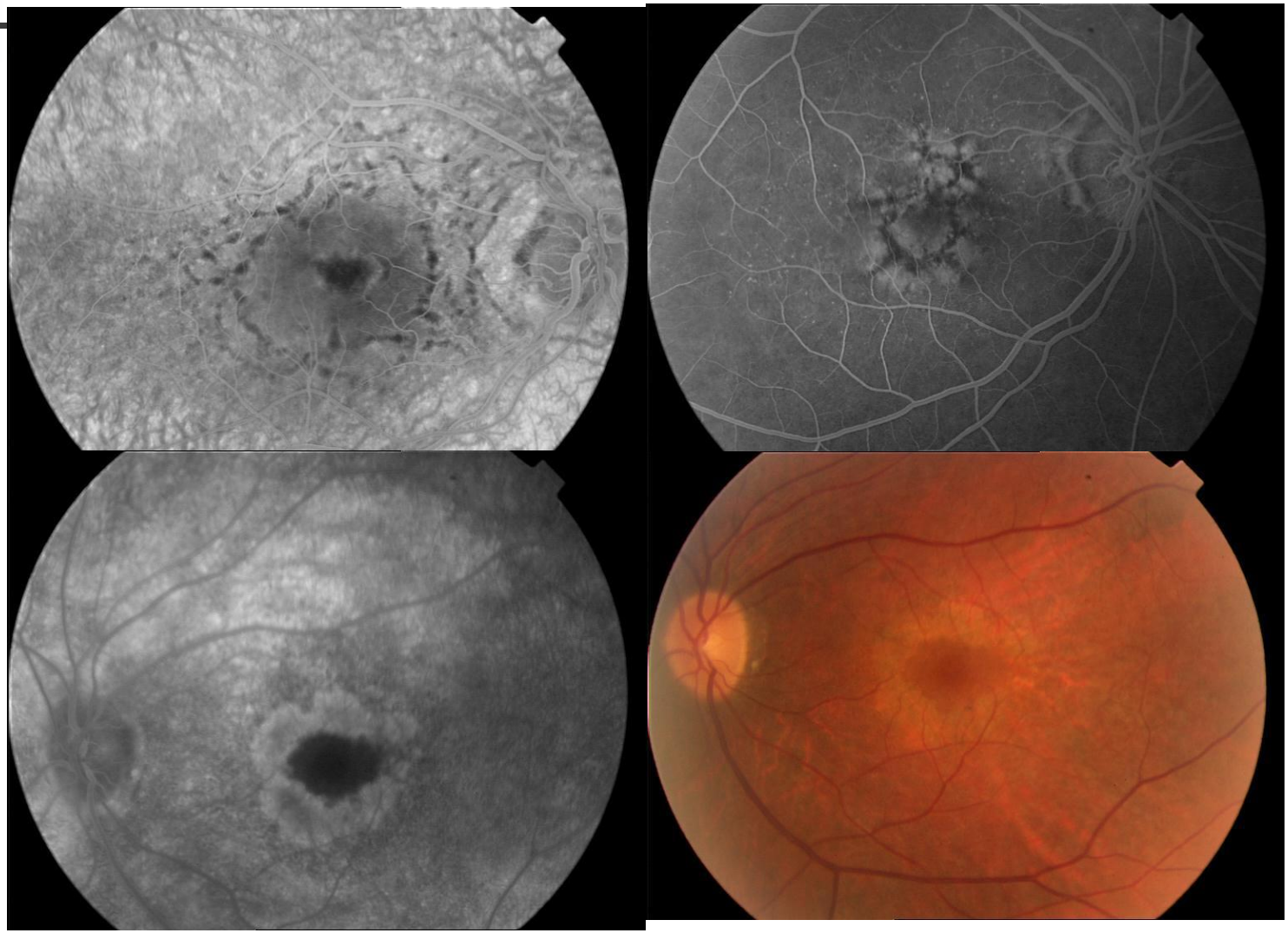

Otofloresans

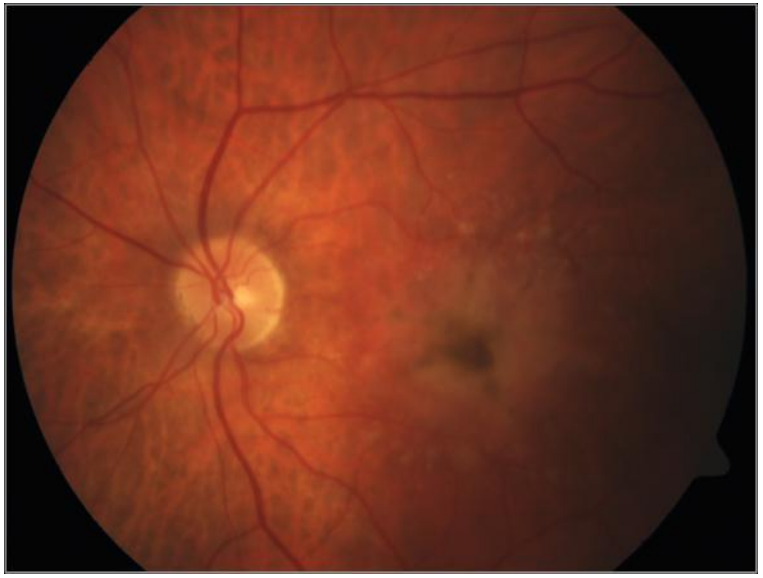

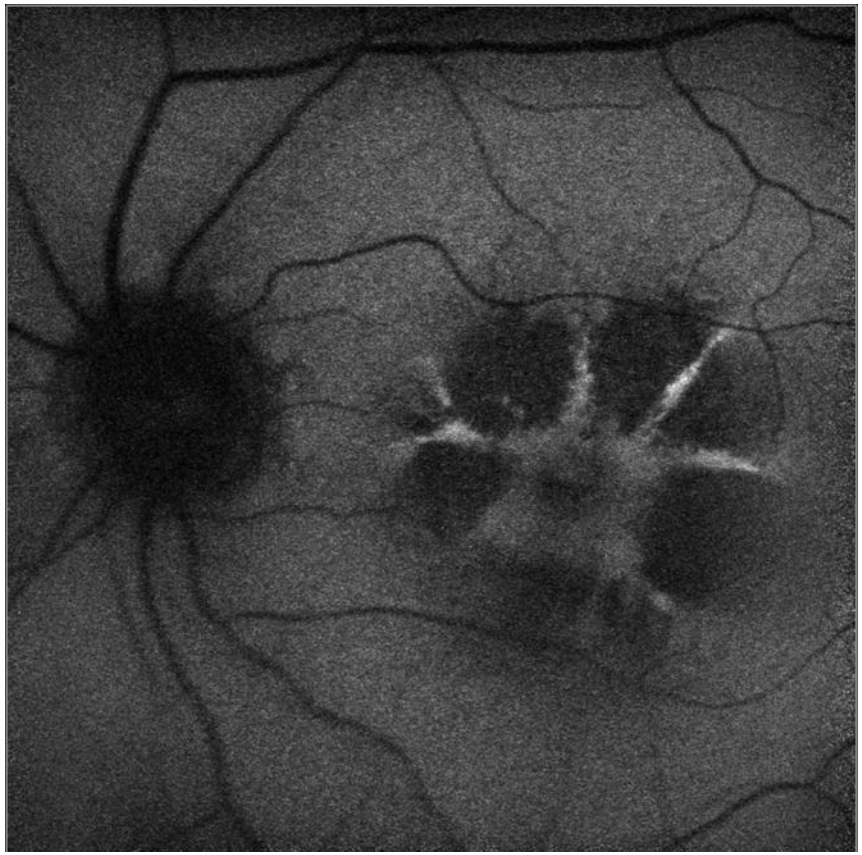

Dr. F. Batıoğlu'nun arşivinden

AOVMD-Adult Vitelliform
40y, E, AÖ, GK: 0.8/0.6

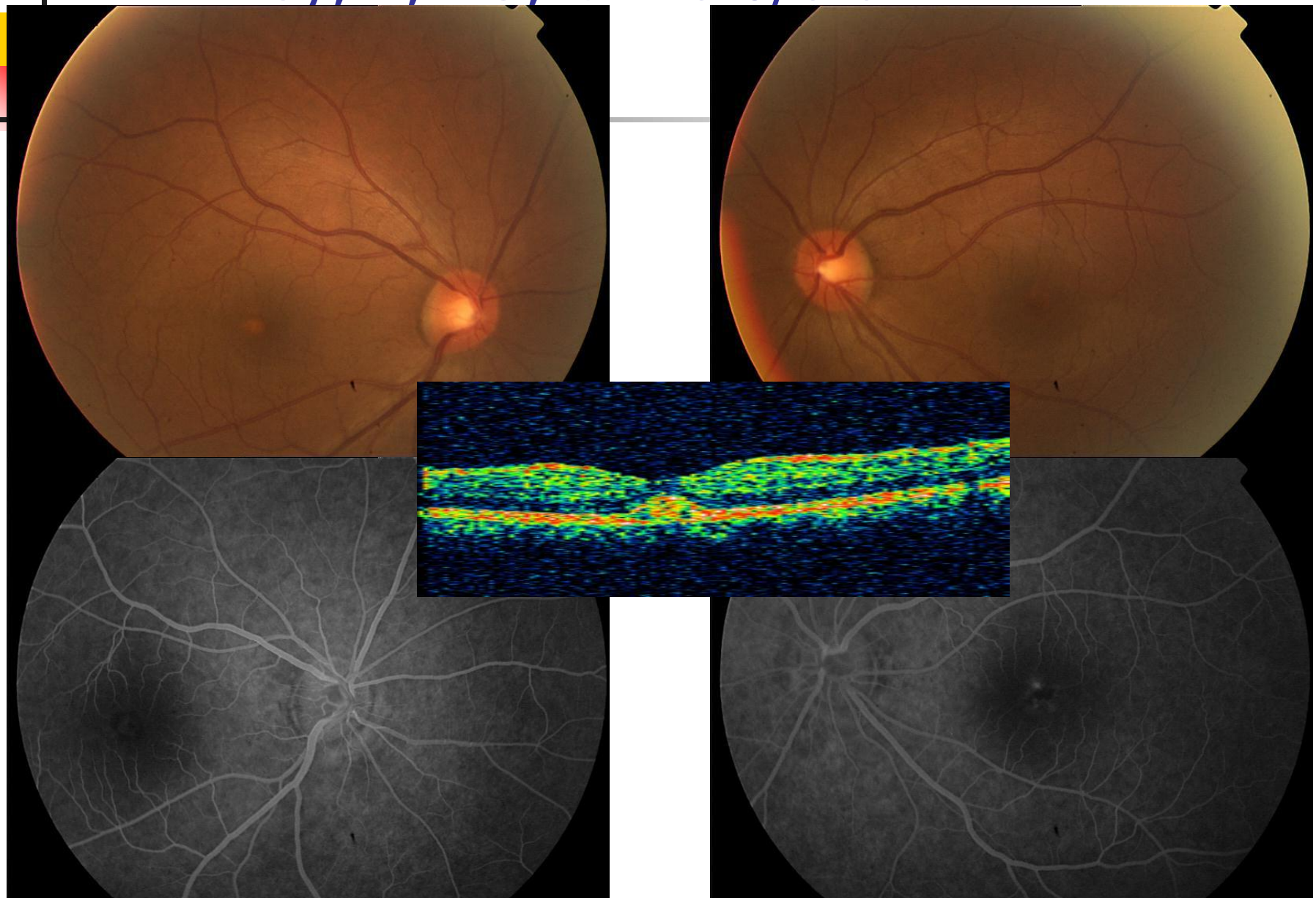

48y, E, SD, GK: Tam/Tam, metamorfopsi

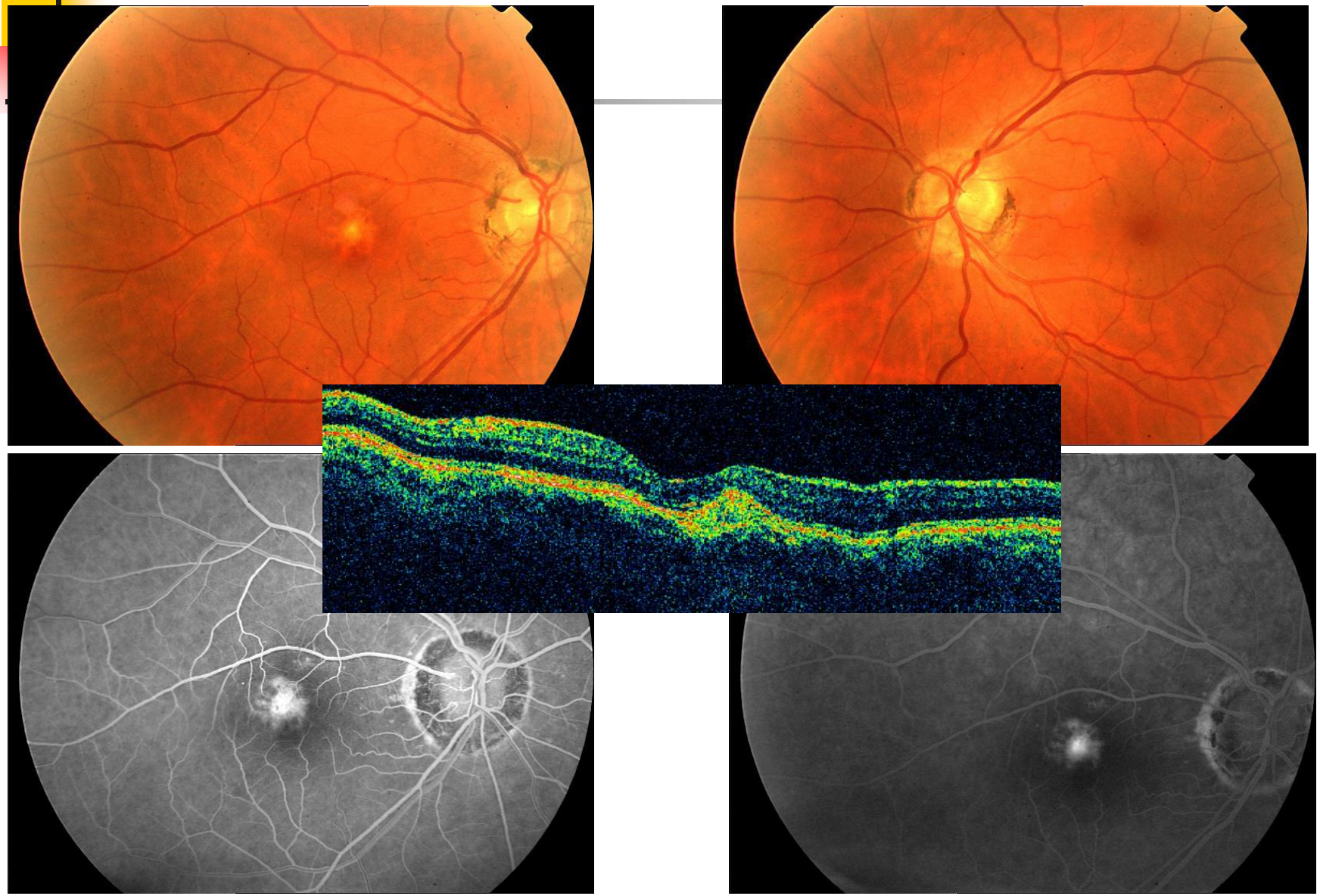

Dominant Drusen

- AD
- Bazal laminar drusen
- OSB nazalinde!
- KNVM seyrek
- Prognoz: iyi

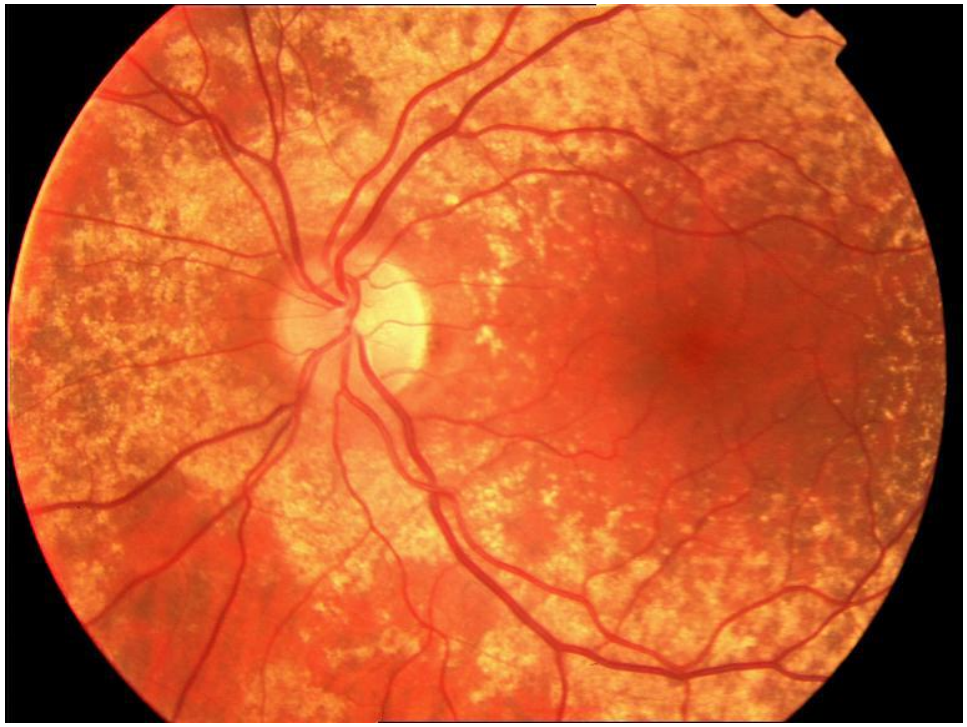

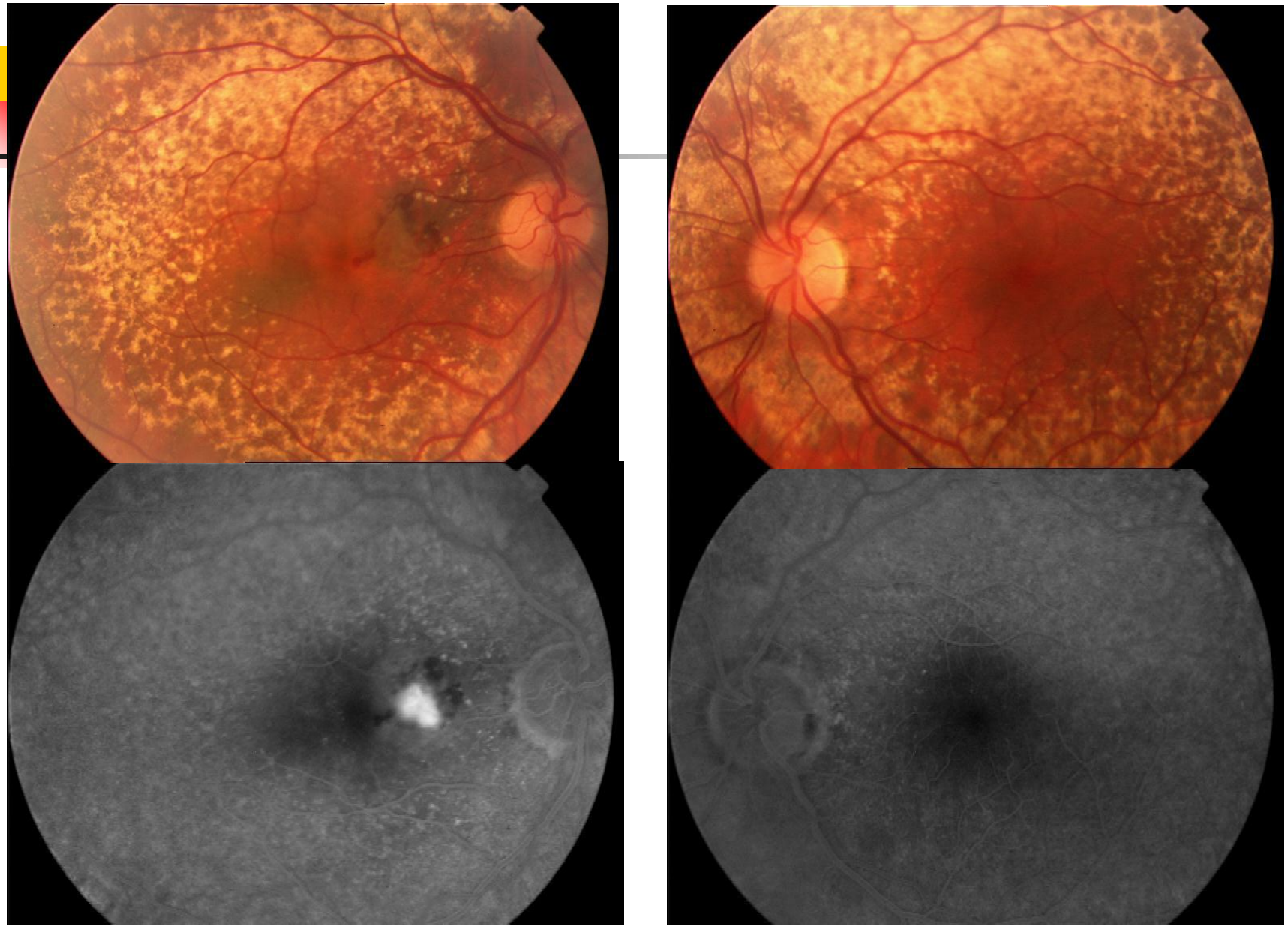

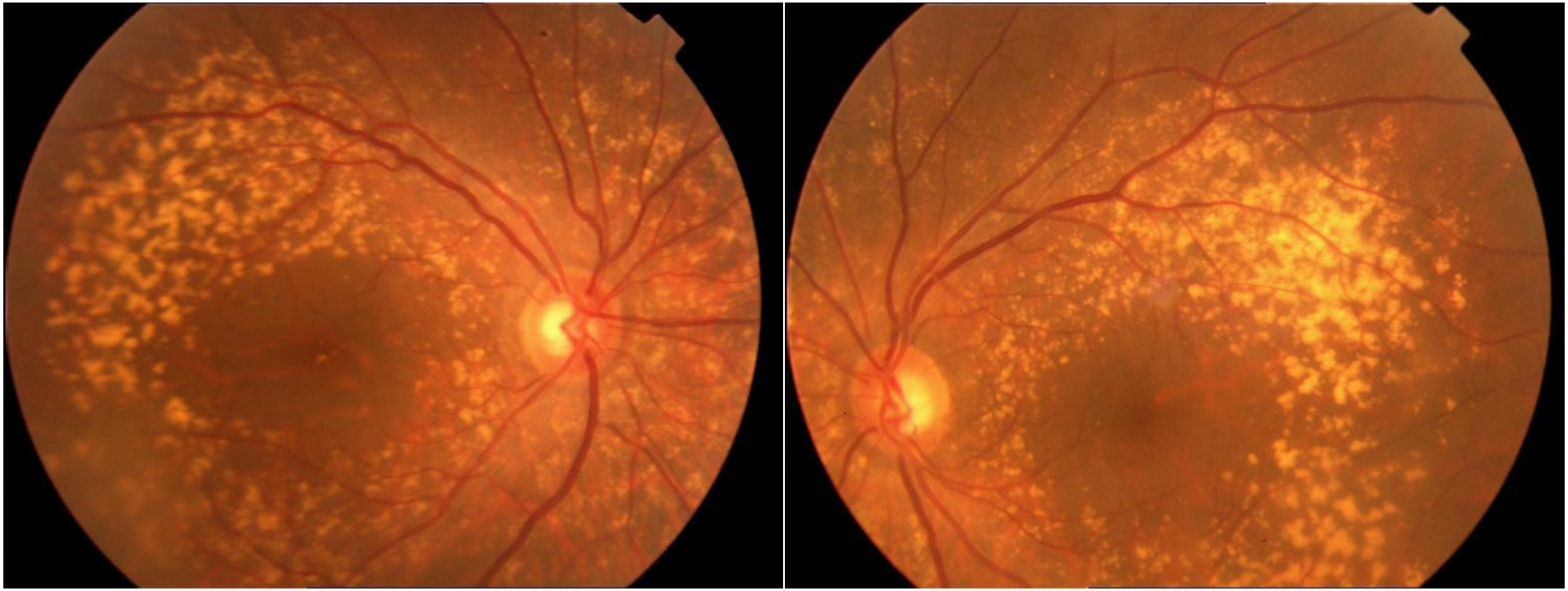

NORTH CAROLINA M.DİSTROFİ

- Maküler kolobom, santral atrofi
- AD, Konjenital, nonprogresif
- KNVM oluşabilir.
- Görme makülanın görünüşünden daha iyi (0.1-1.0 arasında)

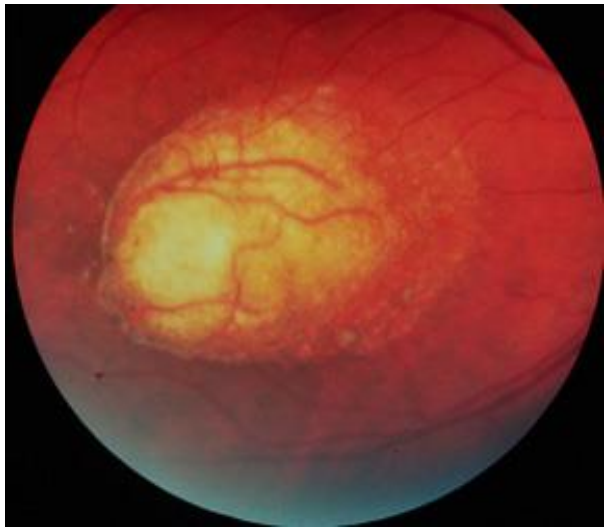

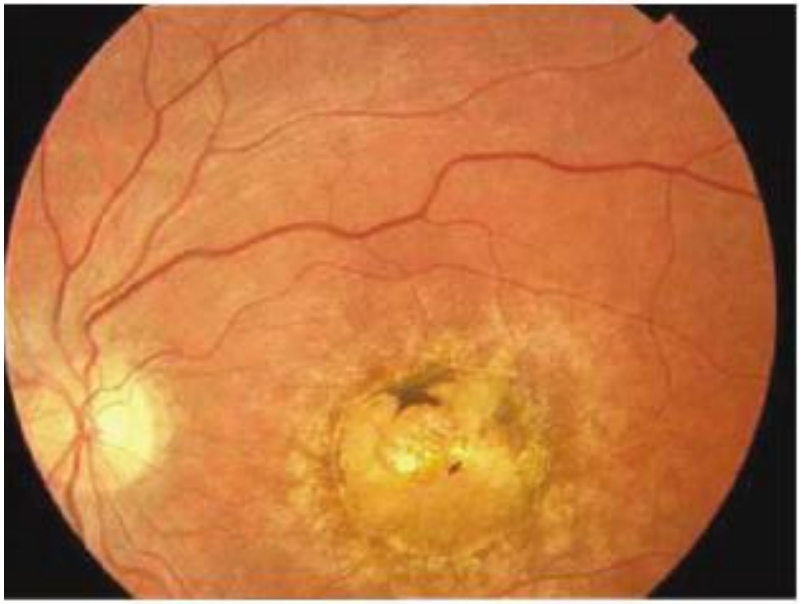

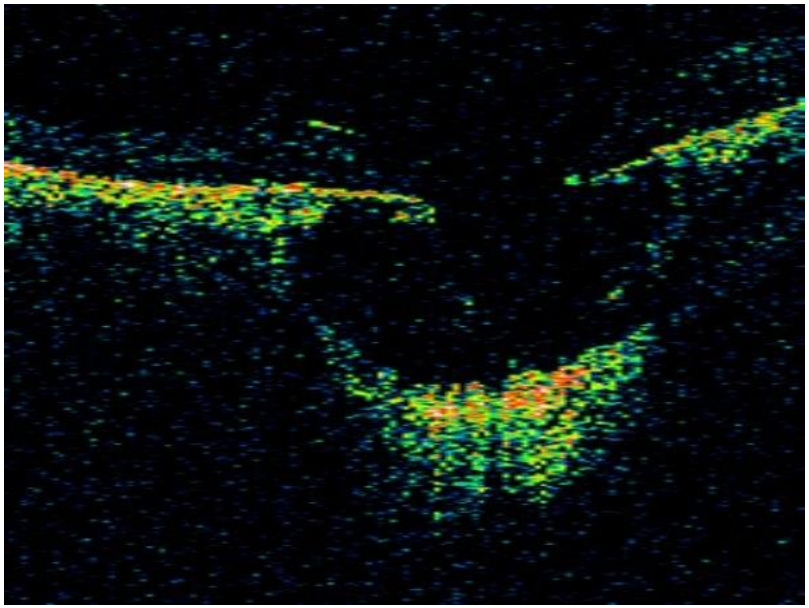

SORSBY MAKÜLER DİSTROFİ

- Erken başlayan SMD, AD,
- 40 yaş civarında bilateral exudatif makülopati
- Geç dönemde: atrofi ve pigmente skar
- Prognoz kötü

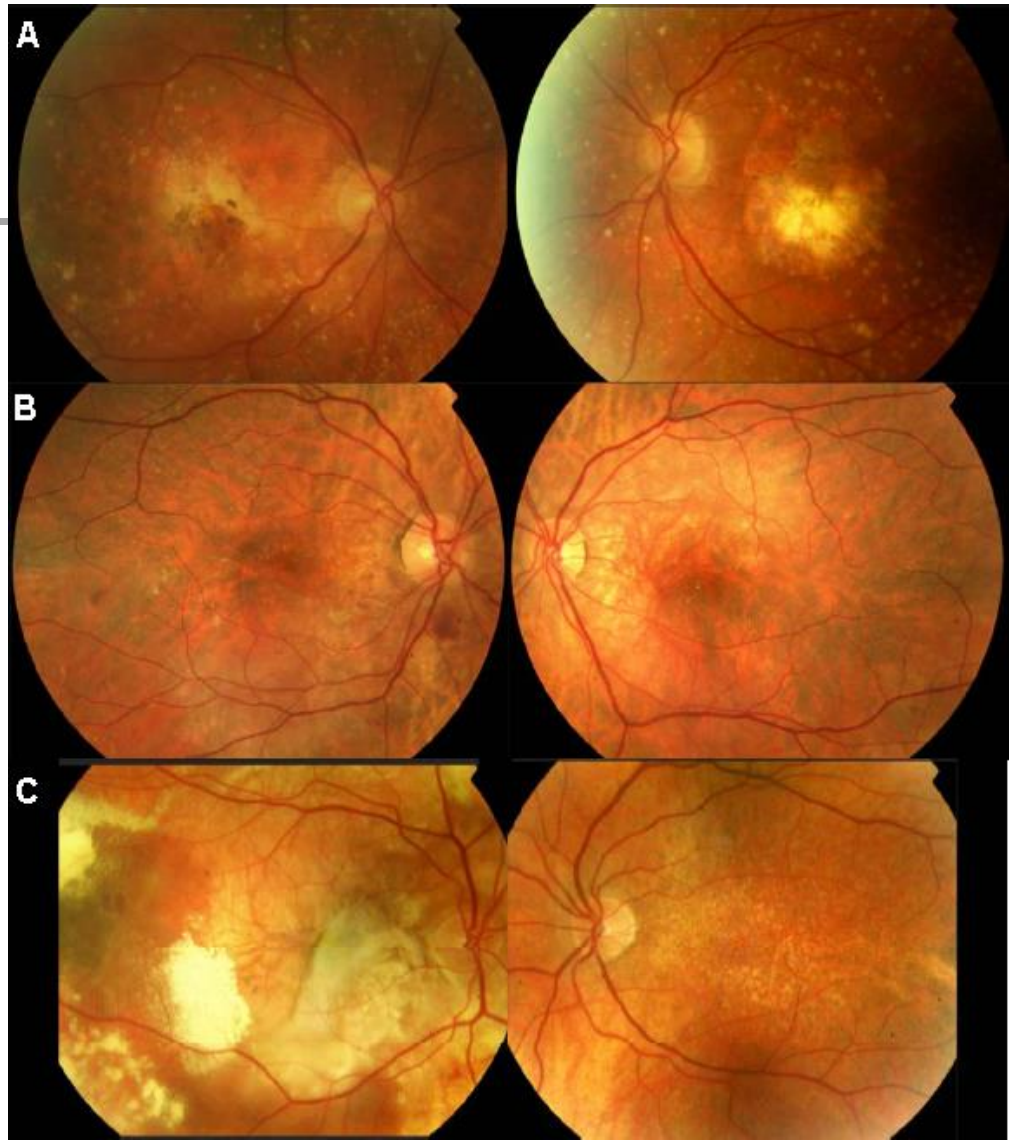
A
B
C

KOROİDAL DİSTROFİLER

Gyrate Atrofi

- Ornitin amino transferaz enz↓
- Plazma ornitin↑
- OR
- İlk dekadda niktalopi
- 4-5. dekada kadar santral görme iyi
- ERG ve EOG suboptimal
- Arka subkapsüler katarakt
- Oral pridoksin takviyesi + Diyette arjinin kısıtlaması

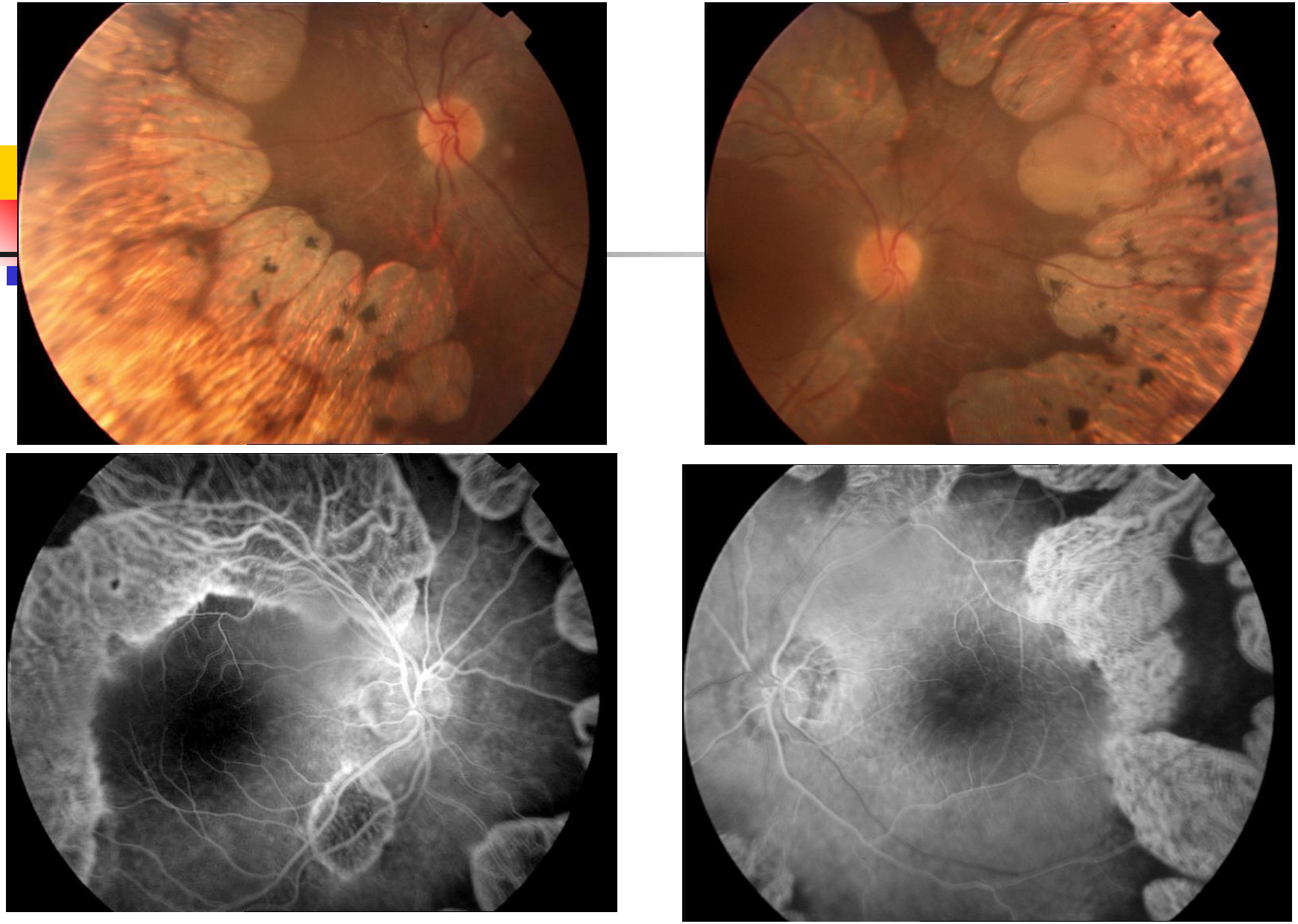

Sarı A, Özdek Ş, Gürelik G, Önol M, Hasanreisoğlu B. Hiperornitinemi ile seyreden bir koryoretinal distrofi: Gyrate Atrofi. Retina-Vitreus, 2002;10:293-299.

Koroideremi

- X-LR, (sadece erkeklerde)
- Progresif gece körlüğü (ilk dekad)
- Midperiferik retinada yama tarzında RPE-koroid atrofisi, pigment kümeleri,
- Geç evre: santral maküler adacık, sklera gözükür hale gelir.

Koroideremi

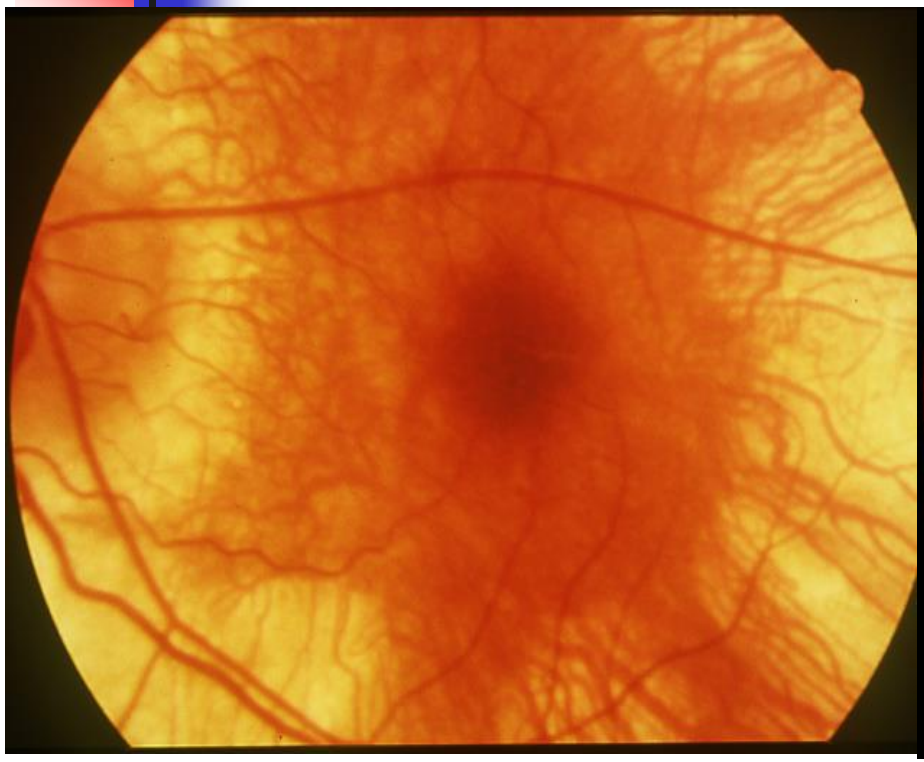

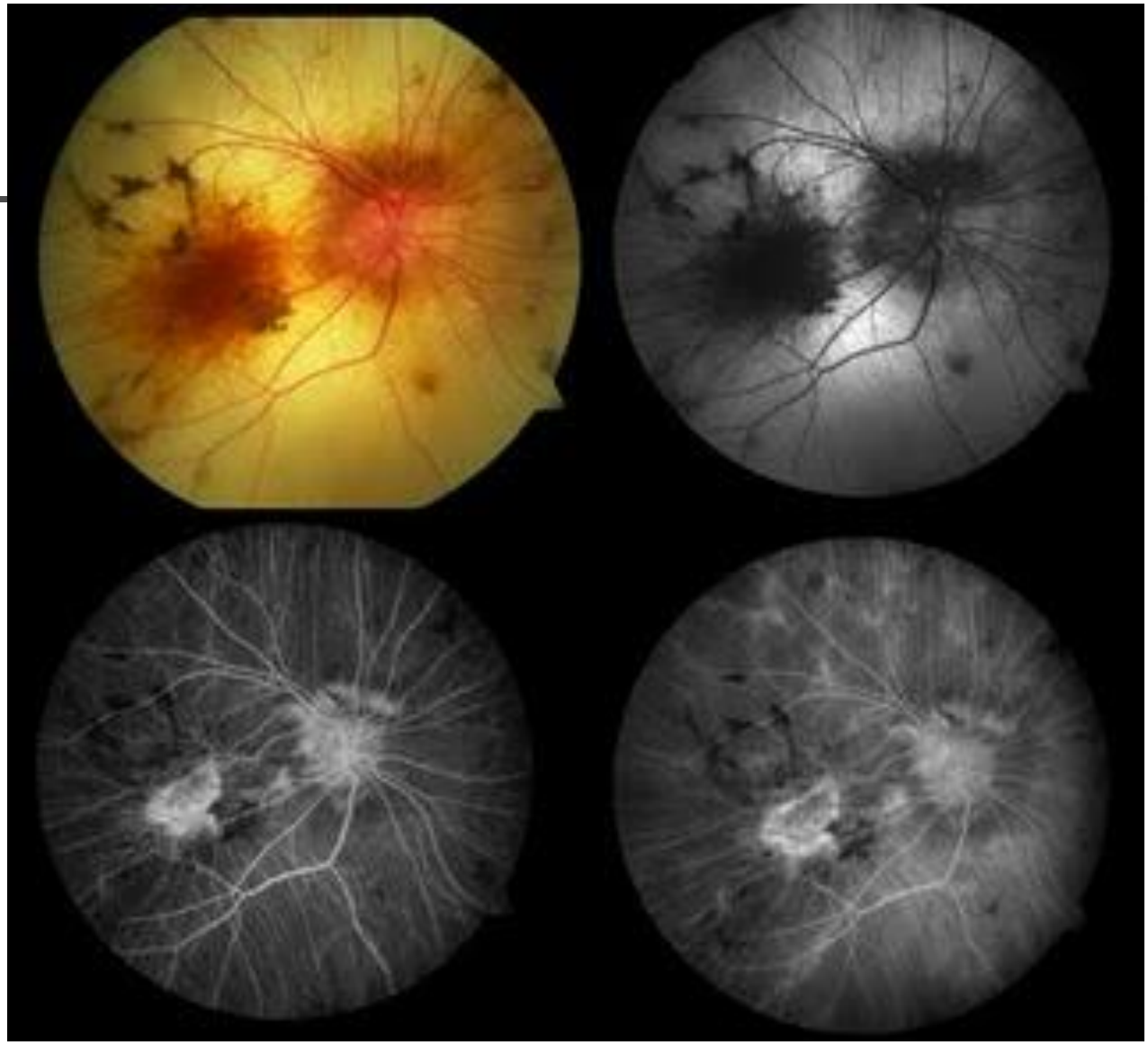

SANTRAL AREOLAR KOROİDAL ATROFİ
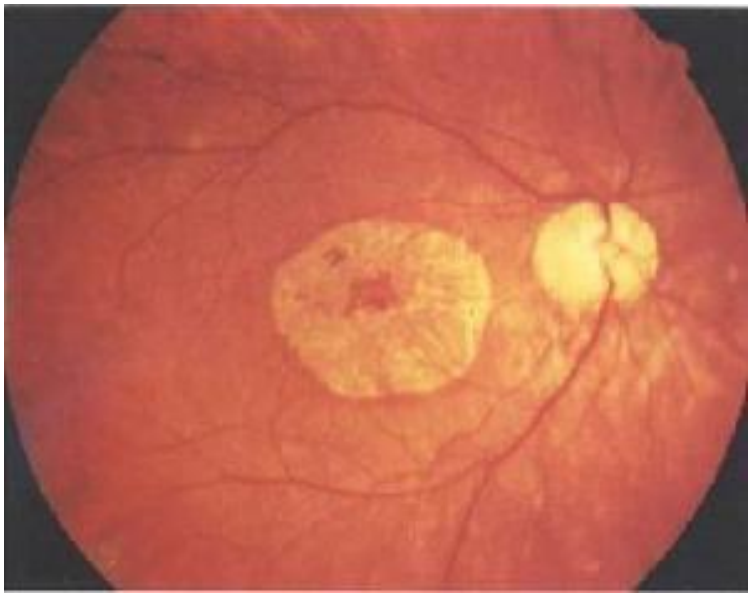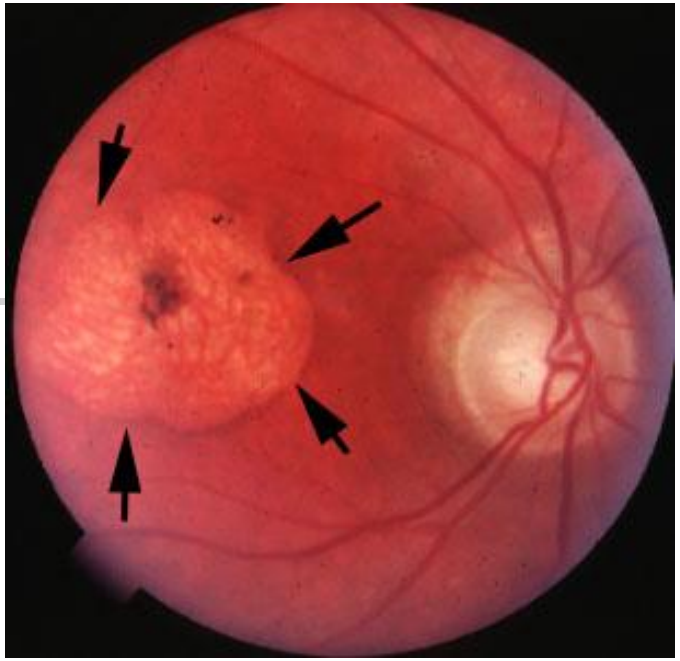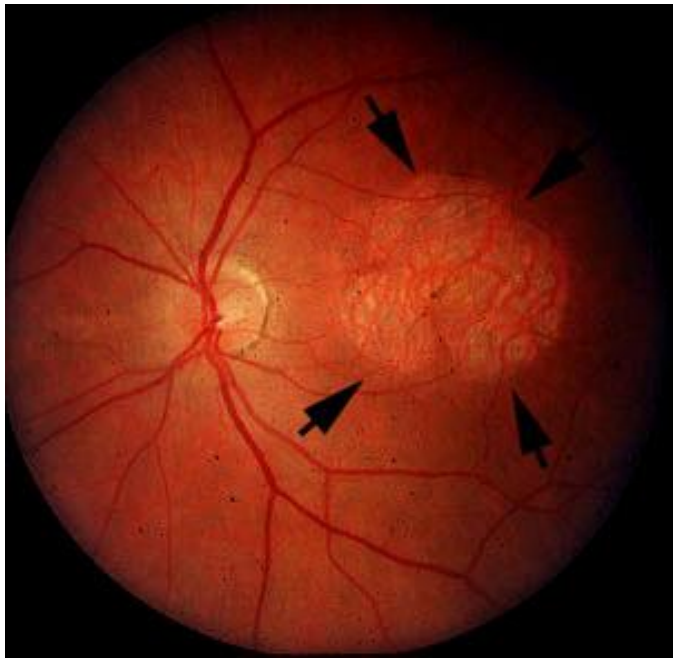
- AD, seyrek, 17p13
- Primer koroidal damar veya RPE distrofisi (ikincil koriokapillaris tutulumu)
- Orta yaşlarda ort çıkar
- 3-10 yılda ilerler.
- Santral RPE ve koriokapillaris atrofisi
- Koni rod distrofisine benzer.